The Central Nervous System

Biology 260
M. Iyengar

Embryonic Development of the NS

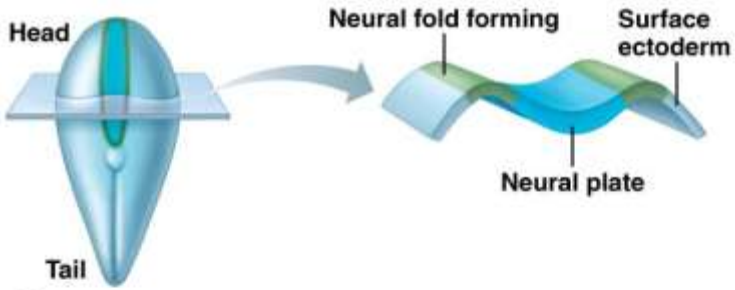

① The neural plate forms from surface ectoderm. It then invaginates, forming the neural groove flanked by neural folds.

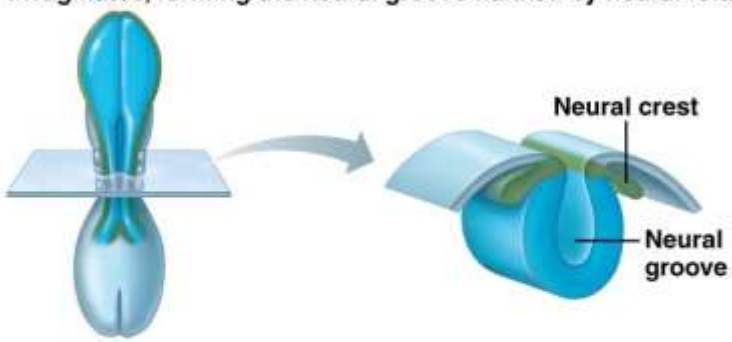

② Neural fold cells migrate to form the neural crest, which will form much of the PNS and many other structures.

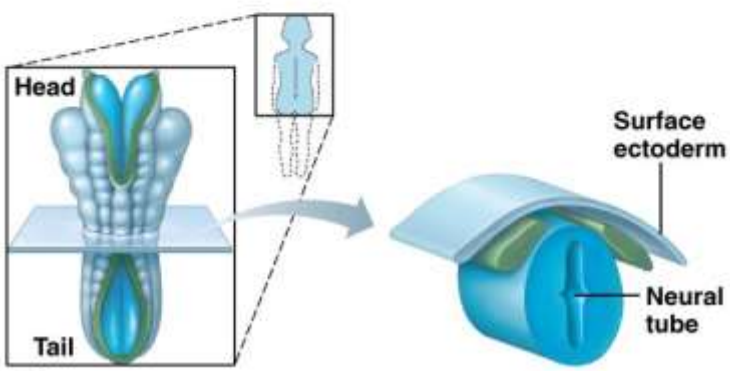

③ The neural groove becomes the neural tube, which will form CNS structures.

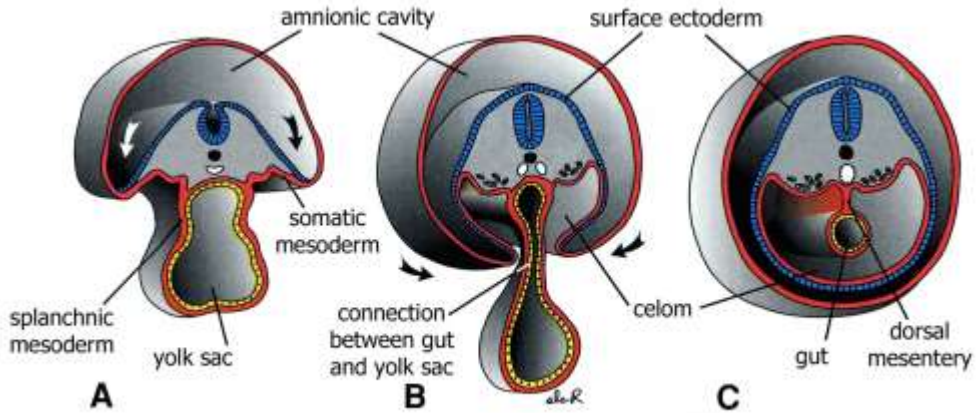

Langman's Medical Embryology, Lippincott, Williams and Wilkins, 9th edition, ISBN: 0-7817-4310-9, figure 13.3, page 288

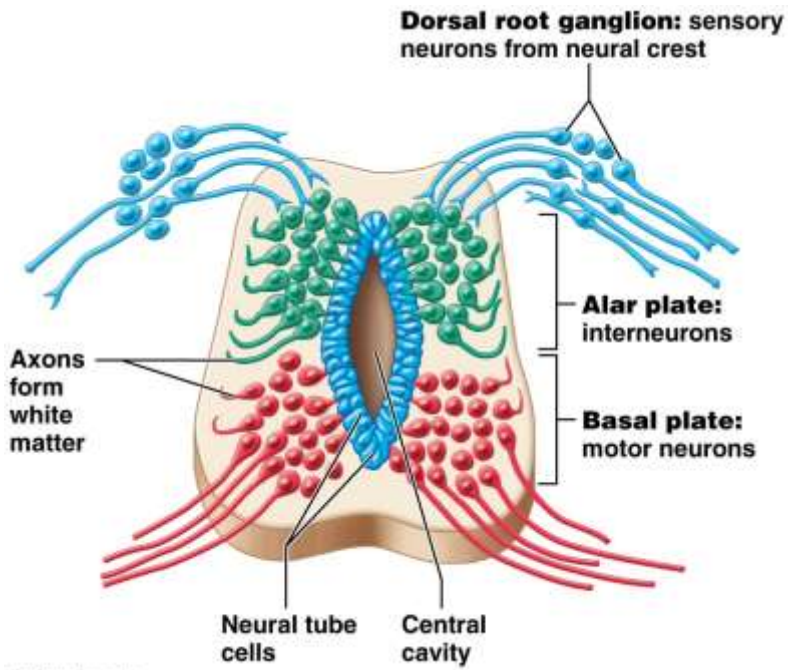

Embryonic Development of the Brain

- Limited room during development results in neural tube bending.
  - Cerebrum grows posterior & lateral
    - Grow over and surround the diencephalon, mesencephalon, metencephalon &, myelenchephalon
  - Cerebral cortex folds to increase surface area
    - **Gyri** - ridges/ bumps
    - **Sulci** - shallow grooves
    - **Fissures** - deep grooves

Embryonic Development of the CNS

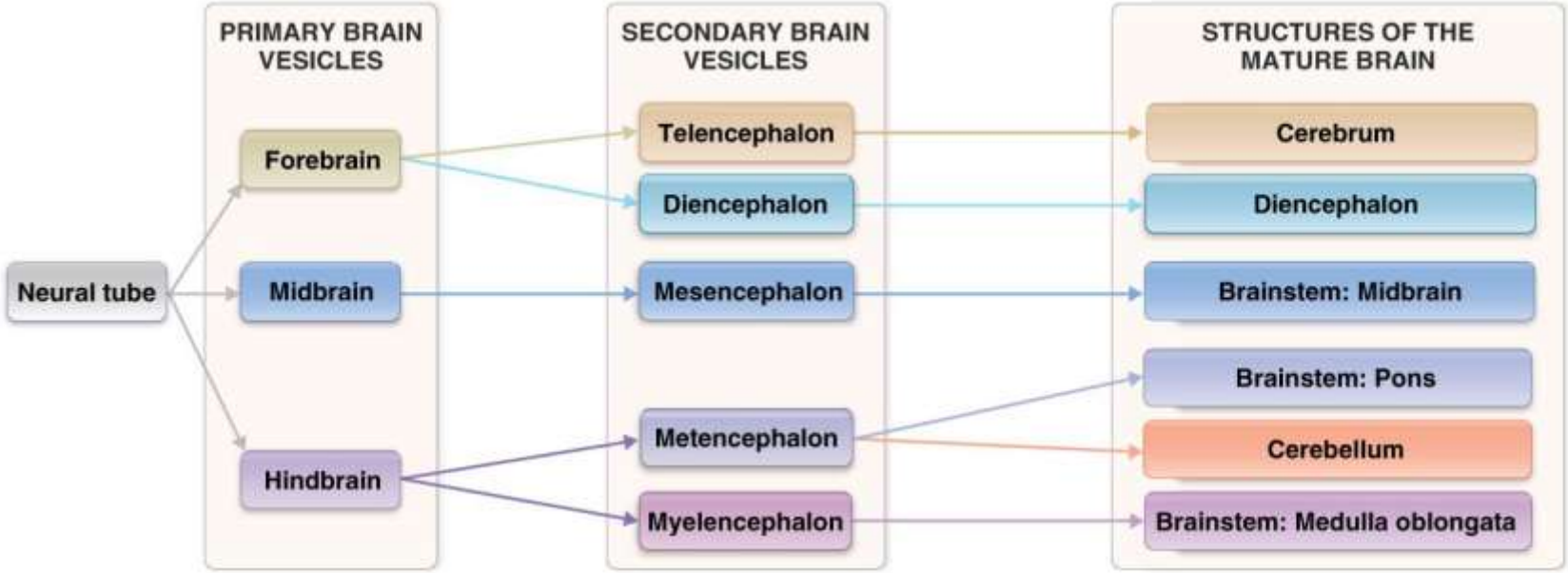

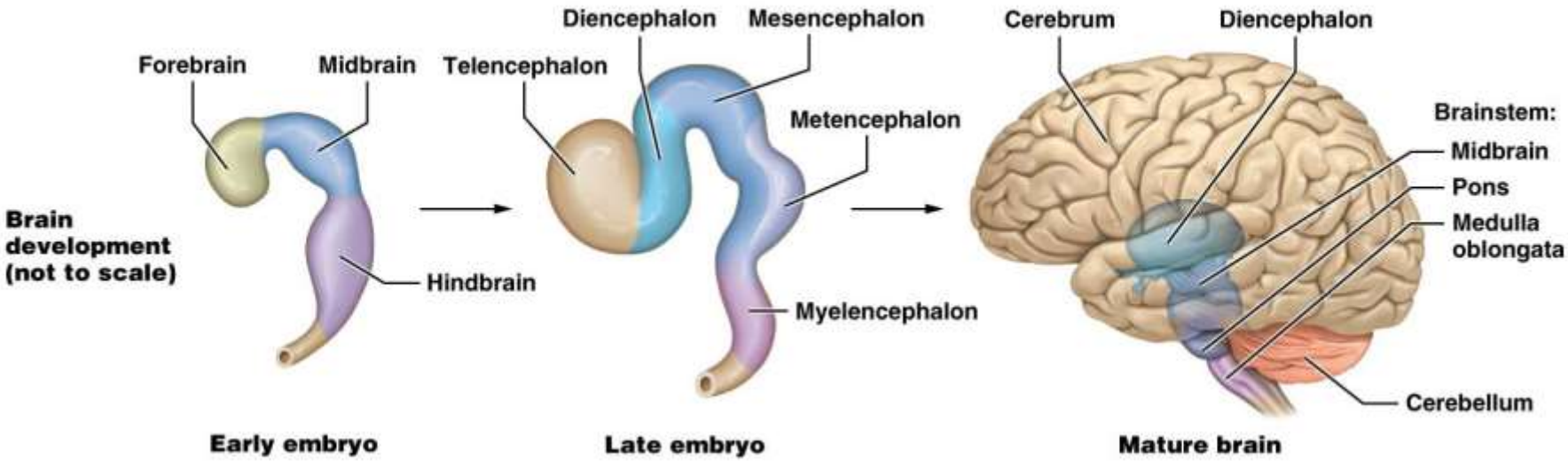

Dorsal Body Cavities and Membranes

- Cranial & Vertebral Cavities - Protect brain & spinal cord
  - Surrounded by the **meninges**

1. **Dura Mater**:
   - Thick layer of dense collagen fibers
   - Periosteal & Meningeal layers
2. **Arachnoid Mater**:
   - Web of collagen + elastic fibers
   - *Subarachnoid space* (brain) – contains CSF
3. **Pia Mater:**
   - Richly vascularized, with thin collagen + elastic fiber layer

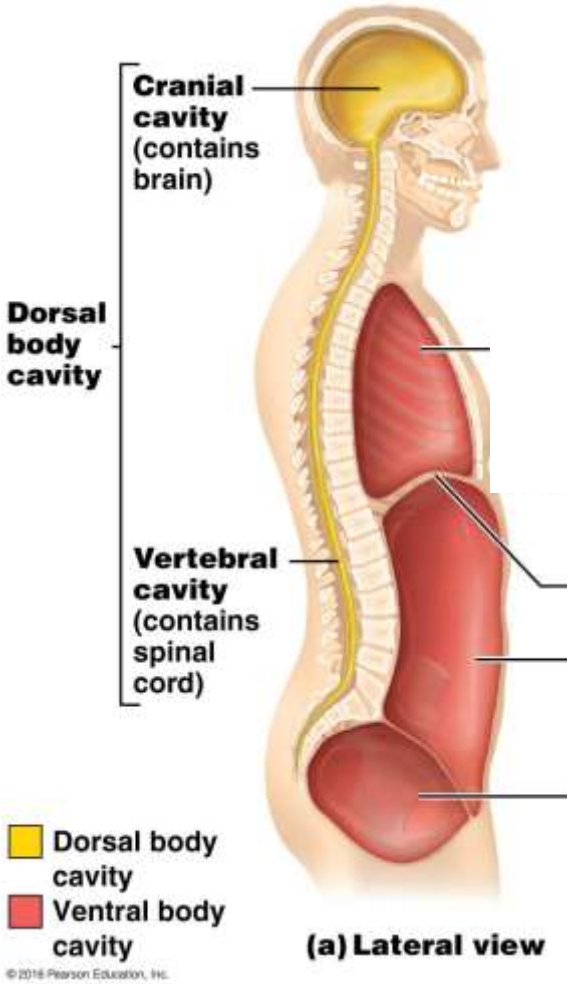

Meninges

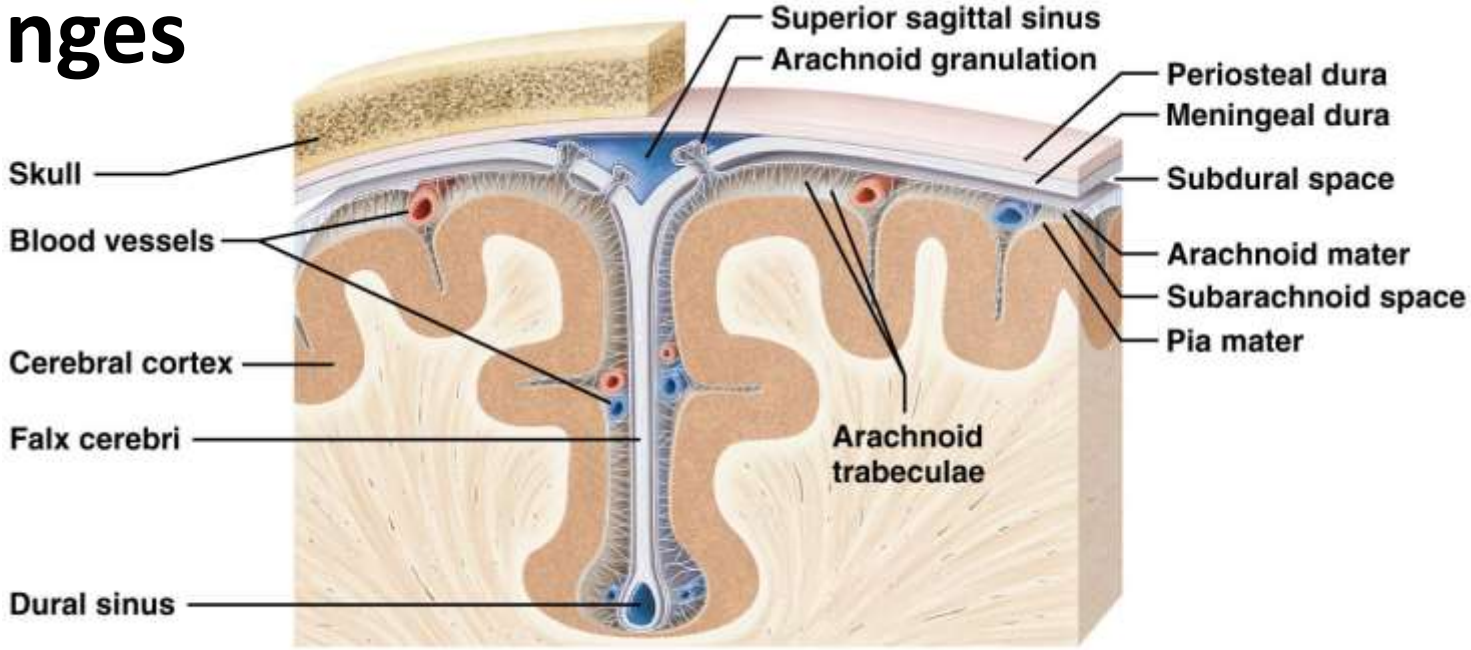

(c) Cranial meninges, frontal section

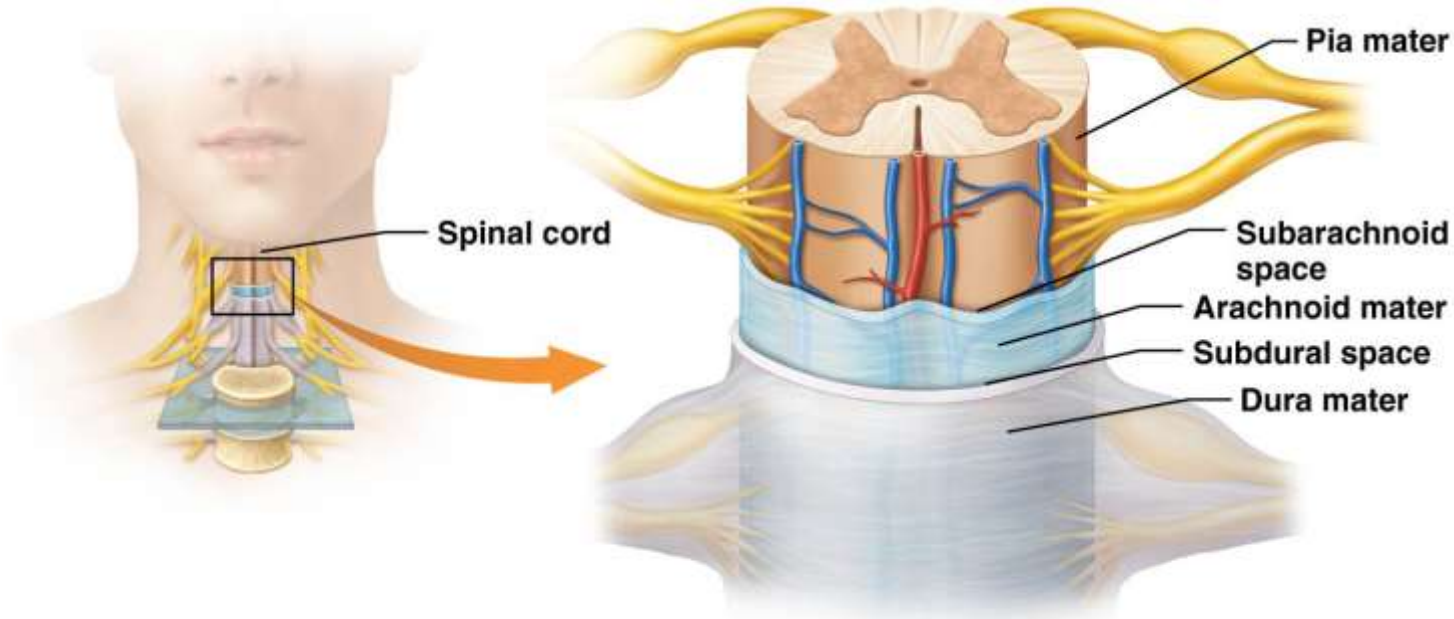

(a) Spinal meninges and spinal cord, anterior view

Cerebrospinal fluid (CSF)

- Watery fluid that fills the hollow cavities and meninges of the brain and the spinal cord.
  - Made by the **choroid plexus** = capillaries + ependymal cells

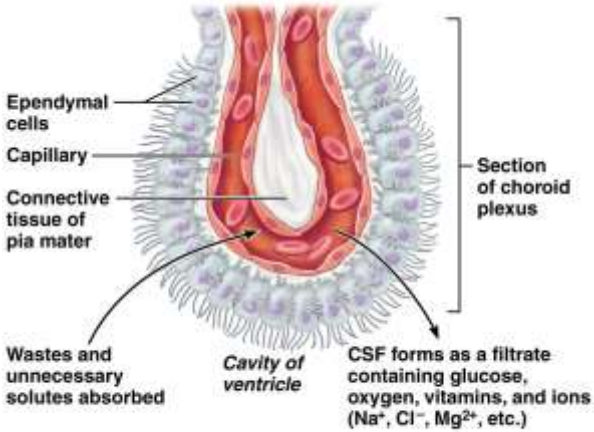

(b) CSF formation by choroid plexuses

1. Provides liquid cushion against blows and jolts

2. Helps to nourish brain and spinal cord

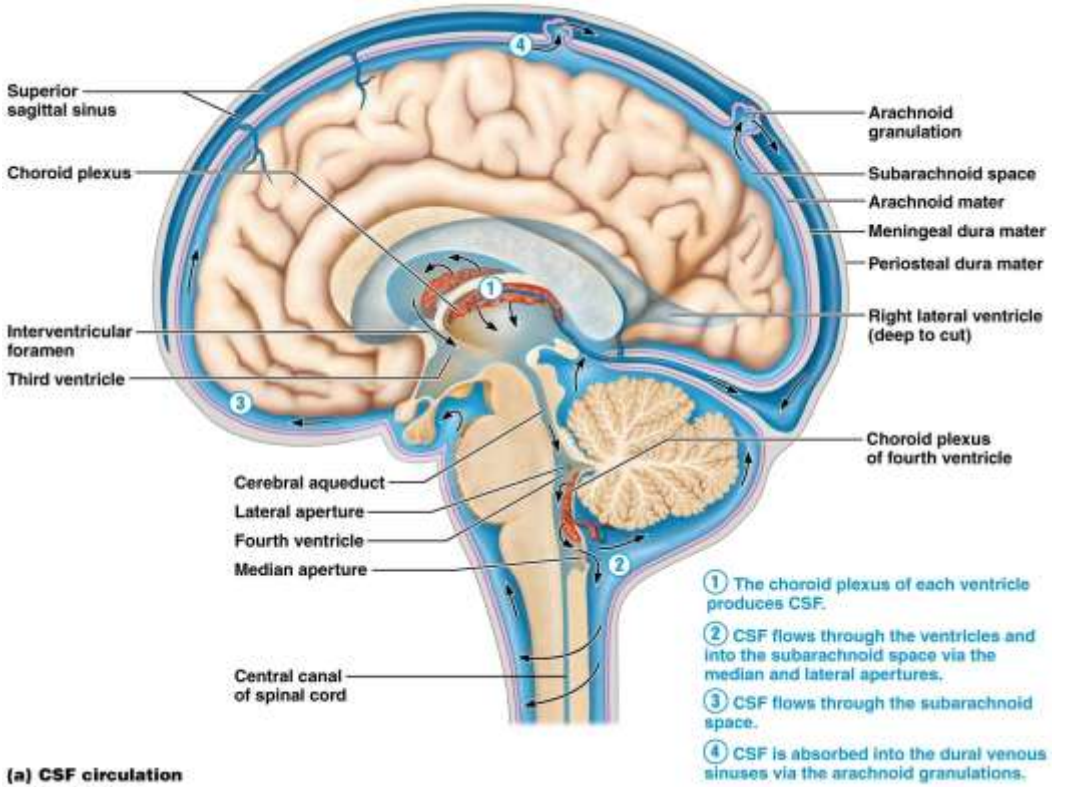

(a) CSF circulation

Overview of the Brain

- Integration, processing, and coordinating sensory data and motor commands.
- Higher functioning such as intelligence, memory, learning, and emotion

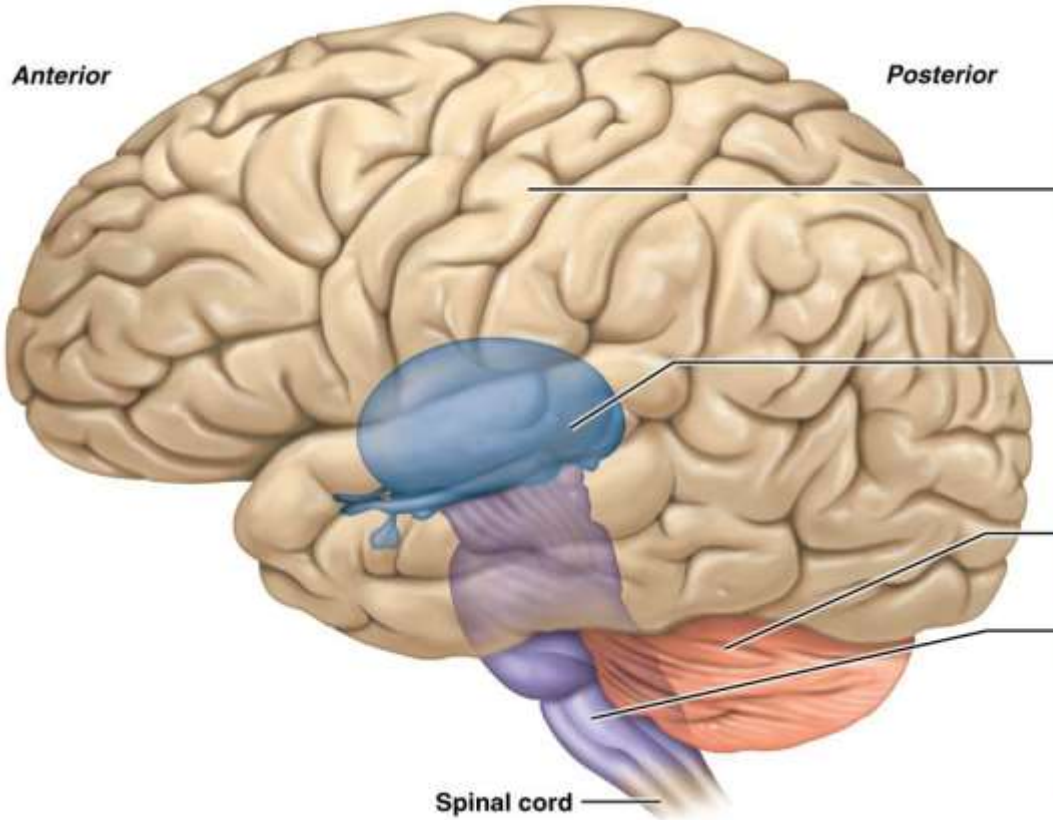

BRAIN DIVISION	FUNCTION
Cerebrum	• Performs higher mental functions • Interprets sensory stimuli • Plans and initiates movement
Diencephalon	• Processes, integrates, and relays information • Maintains homeostasis • Regulates biological rhythms
Cerebellum	• Monitors and coordinates movement
Brainstem	• Maintains homeostasis • Controls certain reflexes • Monitors movement • Integrates and relays information

Ventricles

- Hollow cavities, filled with CSF
  - Continuous with one another and the spinal cord central canal
  - Lined by *choroid plexus* and *ependymal cells*

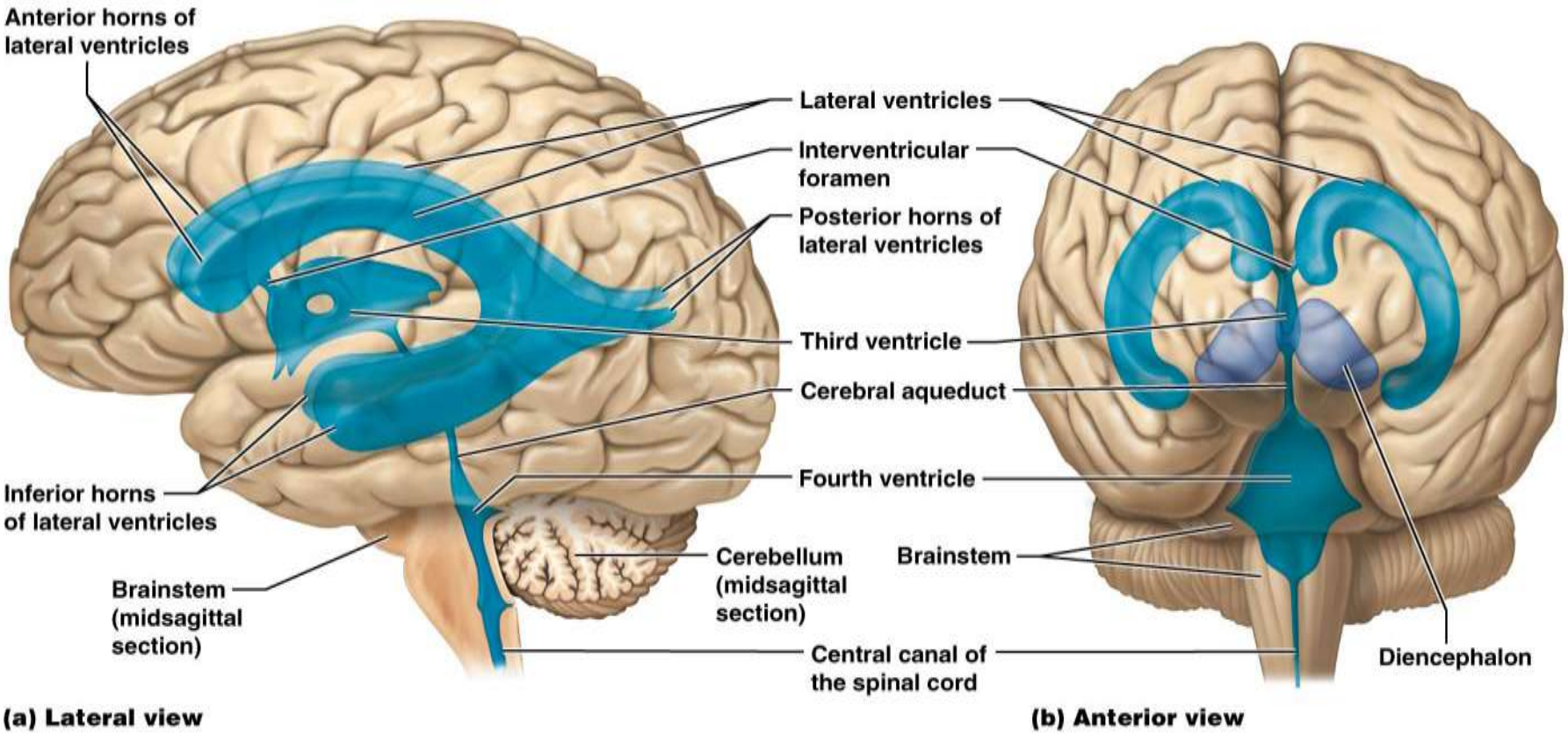

Ventricles

- **Lateral (1st & 2nd) ventricles**:
  - Horns or horseshoe shaped pockets
  - Right and left cerebral hemispheres

- **Third ventricle**:
  - Narrow canal between the diencephalon lobes
  - Cerebral aqueduct at the midbrain connects 3rd and 4th ventricles

- **Fourth ventricle**:
  - Narrow canal between the pons/medulla oblongata & cerebellum
  - Continuous with the spinal cord central canal

Cerebrum

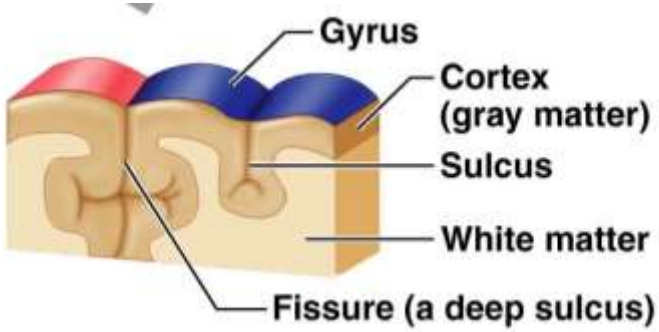

- Tissue regions:
  - **Cerebral cortex** = gray matter
  - **Cerebral white matter**
  - **Basal nuclei** = gray matter islands deep within white matter

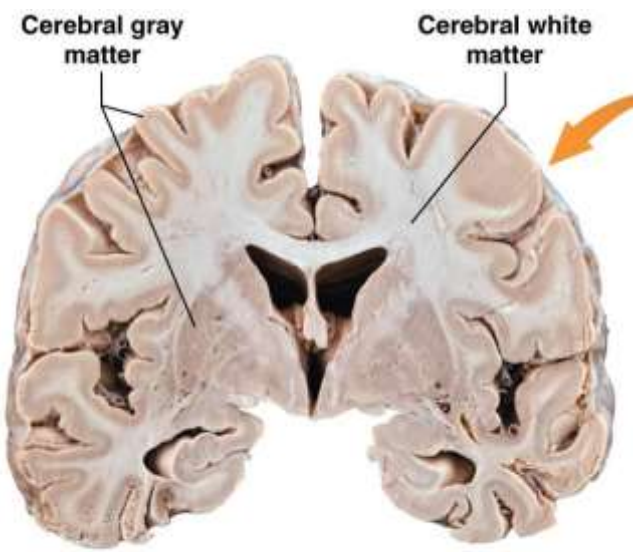

(a) Brain, frontal section

- 2 hemispheres, divided by the **longitudinal fissure**
  - Connected internally by the **corpus callosum**
  - Each hemisphere is **contralateral**
    - Right brain → Left side of body
    - Left brain → Right side of body

Cerebral Cortex

- Superficial, thin layer of gray matter
- Site of conscious mind.
  - sensory perception, voluntary motor output, communication, memory storage, understanding

Structural divisions of the Cerebral Cortex

1. Frontal – anterior to the central sulcus
2. Parietal – posterior to the central sulcus
3. Occipital – posterior and medial to the parietal lobe
4. Temporal – inferior to the lateral sulcus, frontal and parietal lobes
5. Insula - buried under portions of temporal, parietal, and frontal lobes

Basic Functional Divisions of the Cerebral Cortex

1. **Motor areas:**
   - Makes decisions and sends *voluntary* motor output toward muscles including for speech and eye movements

2. **Sensory areas:**
   - Conscious awareness of sensation
   - Sensory areas for each of the major senses
     - Sight, Sound, Taste, Smell, Touch, Somatic (body) sensations, Visceral (organ) sensations

3. **Association areas:**
   - Processes sensory input → gives meaning to the sensation
   - Each sensory cortex area has a specific *sensory association area*
   - ***Multimodal association areas*** receive sensory input from <u>multiple</u> regions of cerebral cortex

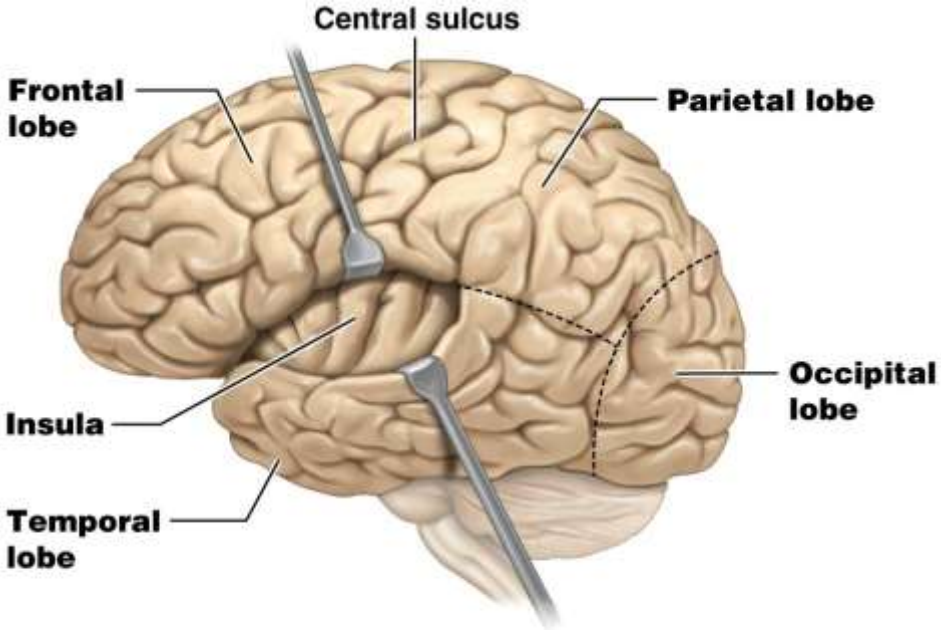

(c) Lateral view (frontal, parietal, and temporal lobes pulled back)

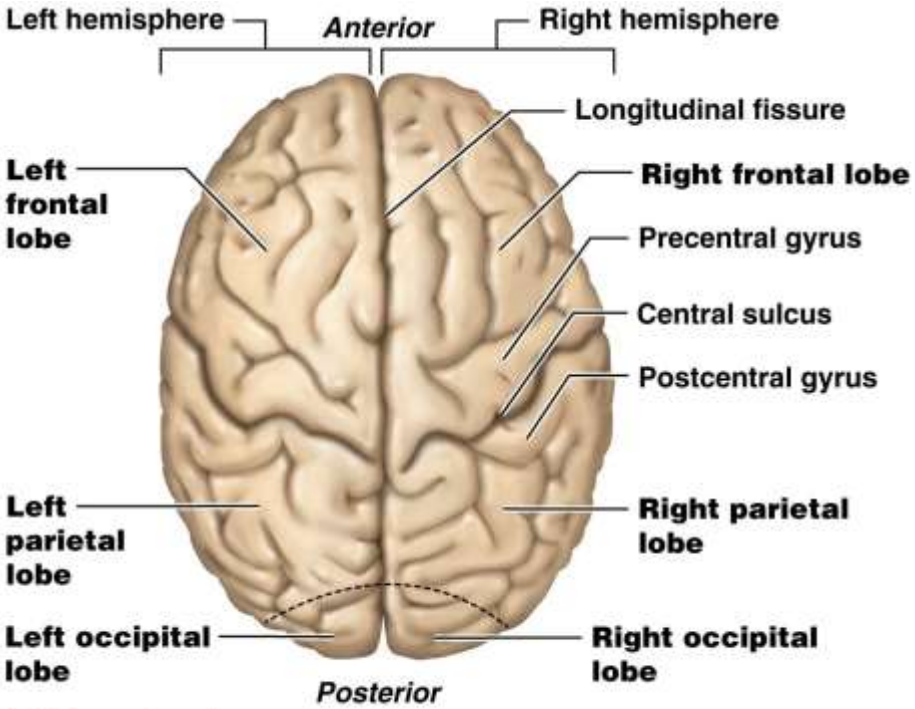

(b) Superior view

Cerebral Cortex: Frontal Lobe

- **Primary (somatic) motor cortex:**
  - Precentral gyrus
  - Controls voluntary (skeletal) muscle movements
  - **Motor homunculus** is the output map of body regions
    - Size of picture = amount of innervation

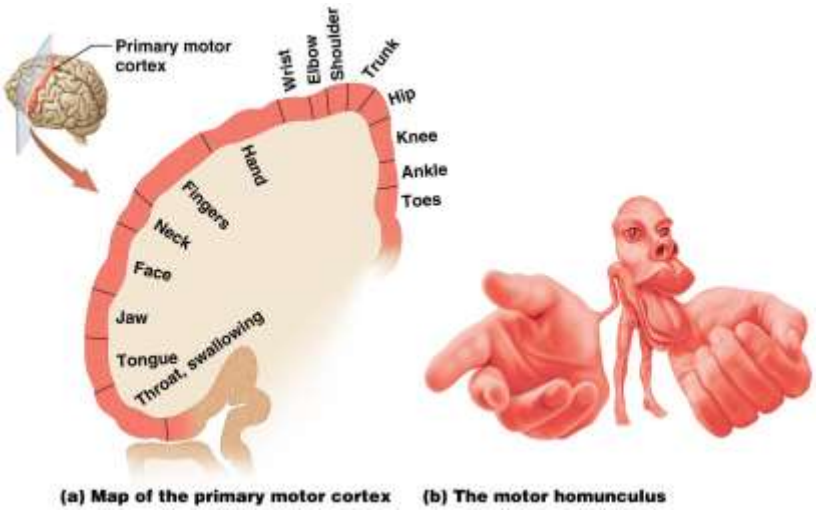

(a) Map of the primary motor cortex (b) The motor homunculus

- **Premotor cortex:**
  - Anterior to the precentral gyrus
  - Helps plan movements by coordinating muscle groups

- **Broca's area**
  - Special motor speech area
    - left → speech production
    - right → emotional overtones
- **Frontal eye field**
  - Controls voluntary eye movements

Cerebral Cortex: Parietal Lobe

- **Primary somatosensory cortex:**
  - Postcentral gyrus
  - Receives sensory information from the body
    - the skin, skeletal muscles, joints, and tendons
  - **Somatosensory homunculus** is the sensory input map of body region
    - Size of picture = amount of innervation

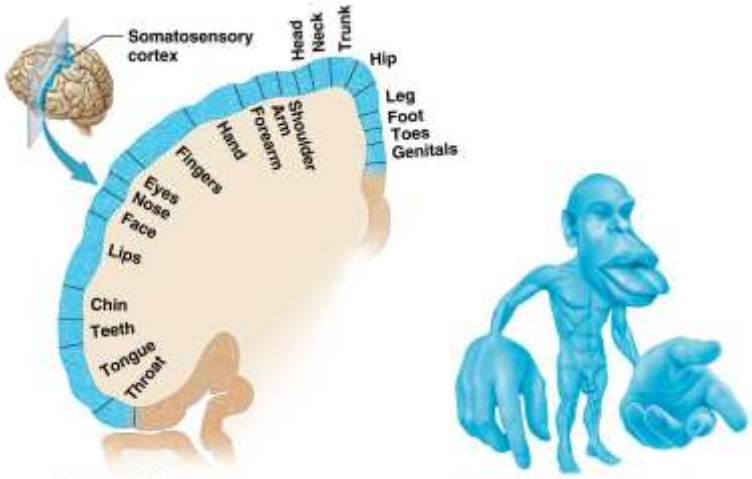

(a) Map of the primary somatosensory cortex (S1)

(b) The sensory homunculus

- **Somatosensory Association Area**
  - Posterior to the postcentral gyrus
  - Processes sensory of input from primary somatosensory cortex

Cerebral Cortex: Occipital Lobe

- **Primary visual sensory cortex:**
  - Tip of the occipital lobe
  - Receives sensory input that originates on the retina
  - Contralateral projection
    - Right eye → left side
    - Left eye → right side

- **Visual association area:**
  - Surrounds the primary visual cortex
  - Analyzing color, form, and movement using past visual experiences
    - Ex: Have I seen this before?

Cerebral Cortex: Temporal Lobe

- **Primary auditory cortex:**
  - Interprets information from inner ear as pitch, loudness, and location

- **Auditory association area:**
  - Perception of sound stimulus and stores memories of sounds

- **Primary olfactory sensory cortex:**
  - Conscious awareness of the sense of smell
  - Sensory input from nose → olfactory bulb → olfactory tract → cortex

Cerebral Cortex: Insula

- **Vestibular (balance) sensory cortex:**
  - Posterior part of insula and adjacent to the parietal cortex
  - Responsible for conscious awareness of balance (position of head in space)

- **Primary gustatory (taste) sensory cortex:**
  - Deep to the temporal lobe
  - Conscious awareness of the sense of taste

- **Visceral (organ) sensory cortex:**
  - Posterior to the gustatory cortex
  - General sensory input from thoracic and abdominal organs
  - Ex. Hunger, pain, pressure, such as upset stomach or full bladder

Multimodal association cortex

- **Anterior association area**
  - **Prefrontal cortex** of the frontal lobe
  - Involved with intellect, cognition, recall, and personality. Working memory

- **Posterior association area**
  - Temporal, parietal, and occipital lobes
  - Pattern and face recognition.
  - Localizing us and our surroundings in space
  - *Wernicke's area* – understanding written and spoken language

- **Limbic association area**
  - Provides emotional impact that makes a scene important to us and helps establish memories

Cerebral White Matter

- Communication between cerebral areas, and between cortex and lower CNS
  - **Association** – sensory → association areas of same hemisphere
  - **Commissural** – between hemispheres
  - **Projection fibers** – cortex → lower CNS, or lower CNS → cortex

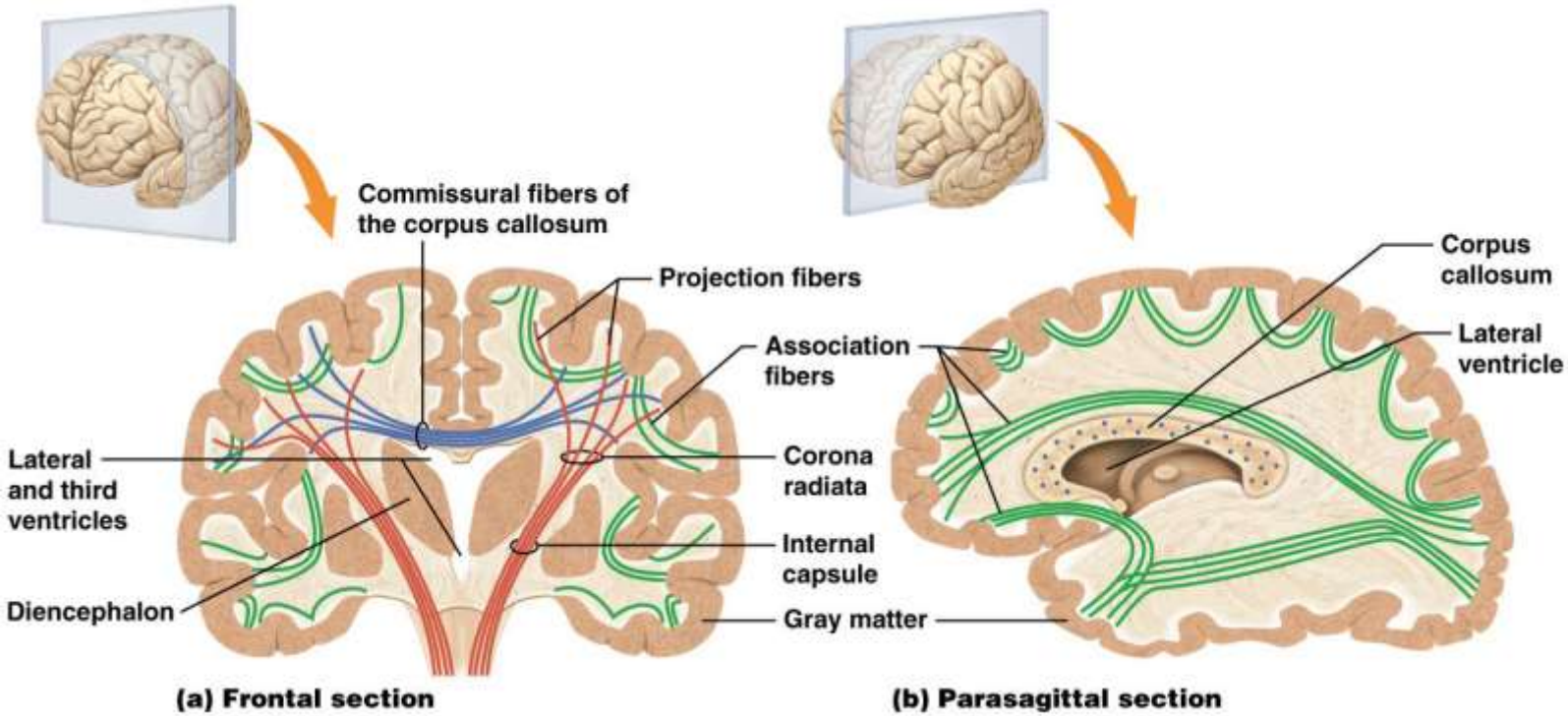

Basal Nuclei

- Grey matter islands deep to the white matter tracts
  - **Caudate nucleus, Putamen, Globus pallidus**
  - Influence & regulate muscle movements
  - Inhibit antagonistic & unnecessary movements

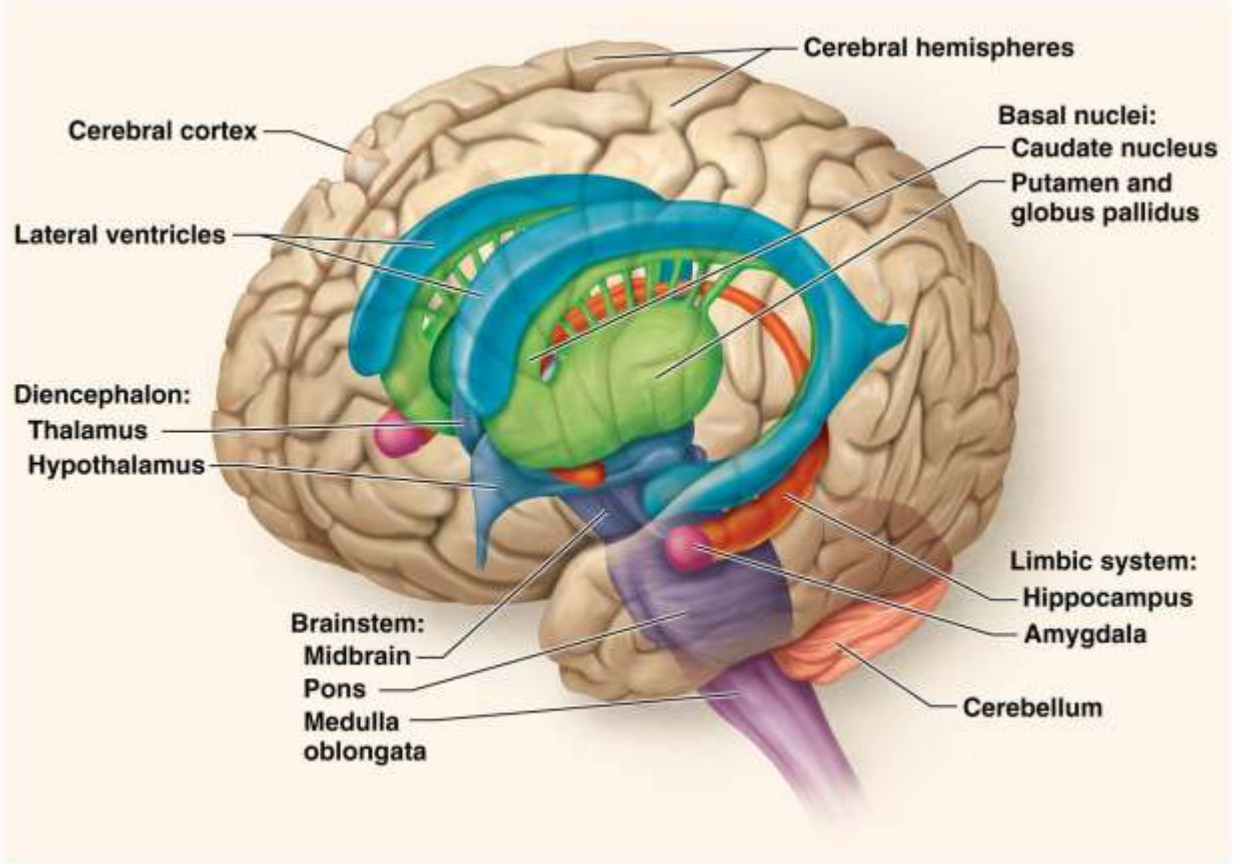

The Limbic system Anatomy

- Structures are on medial aspect of cerebral hemispheres
- Emotional, or affective (feelings), brain.

- Express emotions through gestures and resolves mental conflict when frustrated

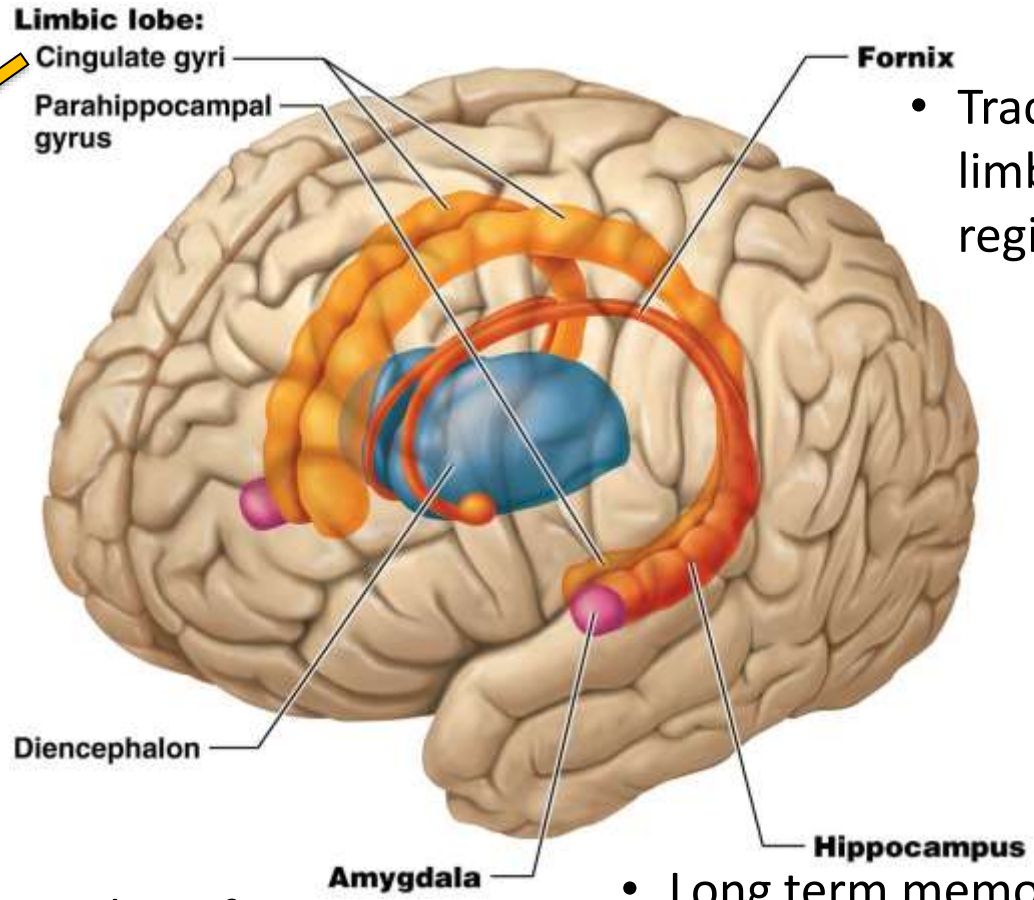

- Tracts that link the limbic system regions

- Elicits fear response

- Long term memory and behavior
- Link between ANS and stress

Diencephalon

- Core of the forebrain surrounded by the cerebrum
  - Three grey matter structures that enclose the 3rd ventricle
- **Thalamus**
  - Two, egg-shaped nuclei that make up the superolateral walls of the 3rd ventricle
  - Sorts, edits, and relays messages coming to or from the cerebral cortex
- **Epithalamus**
  - Most dorsal region of diencephalon
  - Includes pineal gland
  - Secretes melatonin (under hypothalamus control)
    - Controls sleep-wake cycle

Diencephalon

- **Hypothalamus**
  - Inferior region,
    - Connected to the **pituitary gland (PG)** by the **infundibulum**
  - Makes hormones that controls APG and hormones that are stored in PPG
  - Automatic regulation of:
    - Temperature
    - Food and water intake
    - Sleep-wake cycles
    - Emotional responses – part of the limbic system
  - **Mammillary bodies**
    - Paired, anterior nuclei that act as olfactory relay stations

Diencephalon

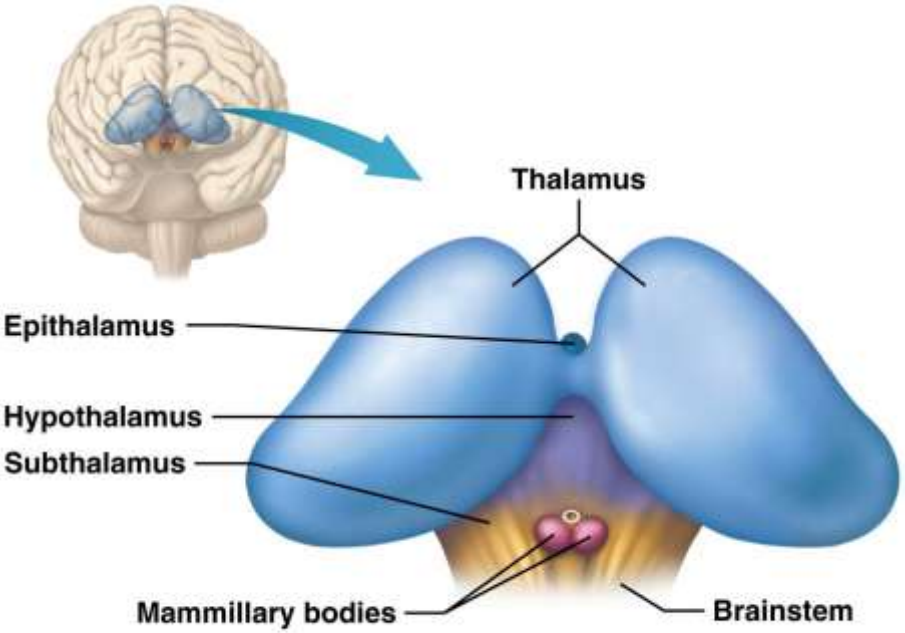

(a) Diencephalon, anterior view

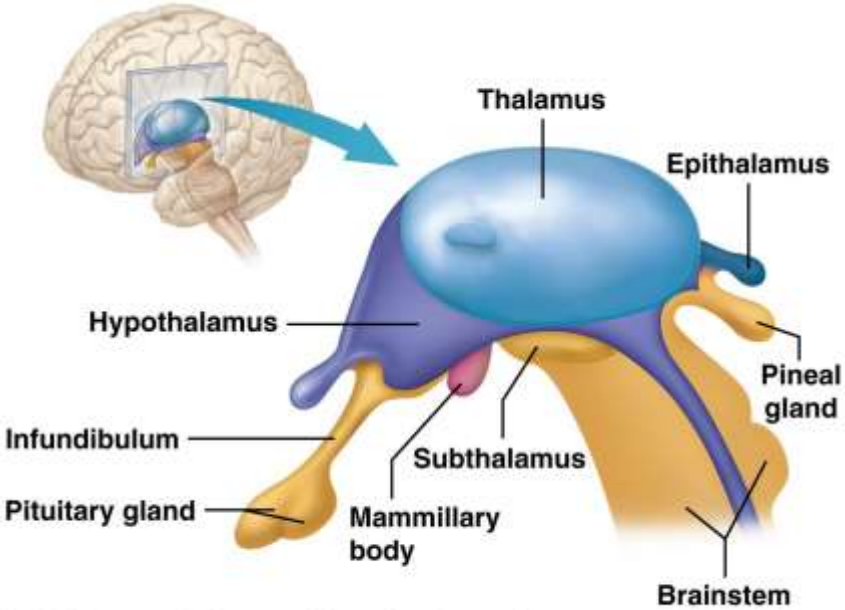

(c) Diencephalon, midsagittal section

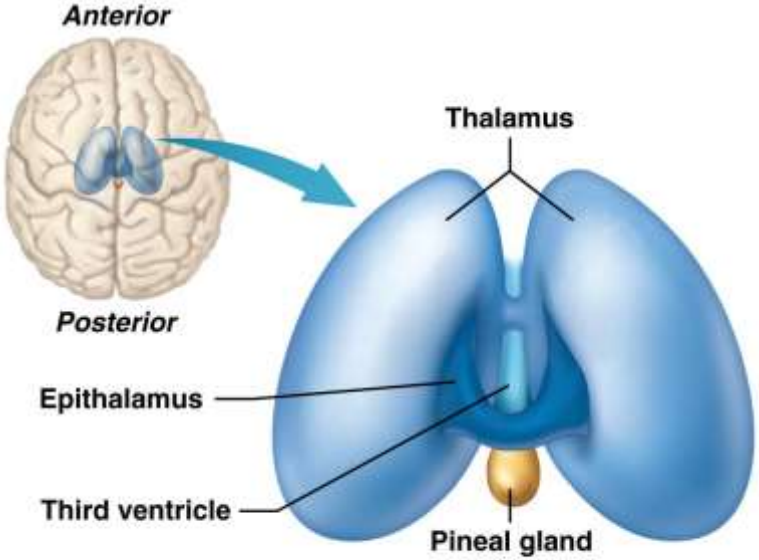

(b) Diencephalon, superior view

Overview of the Brainstem

- Most inferior part of the brain
  - Grey matter surrounded by white matter

1. Midbrain
2. Pons
3. Medulla oblongata
4. Reticular formation

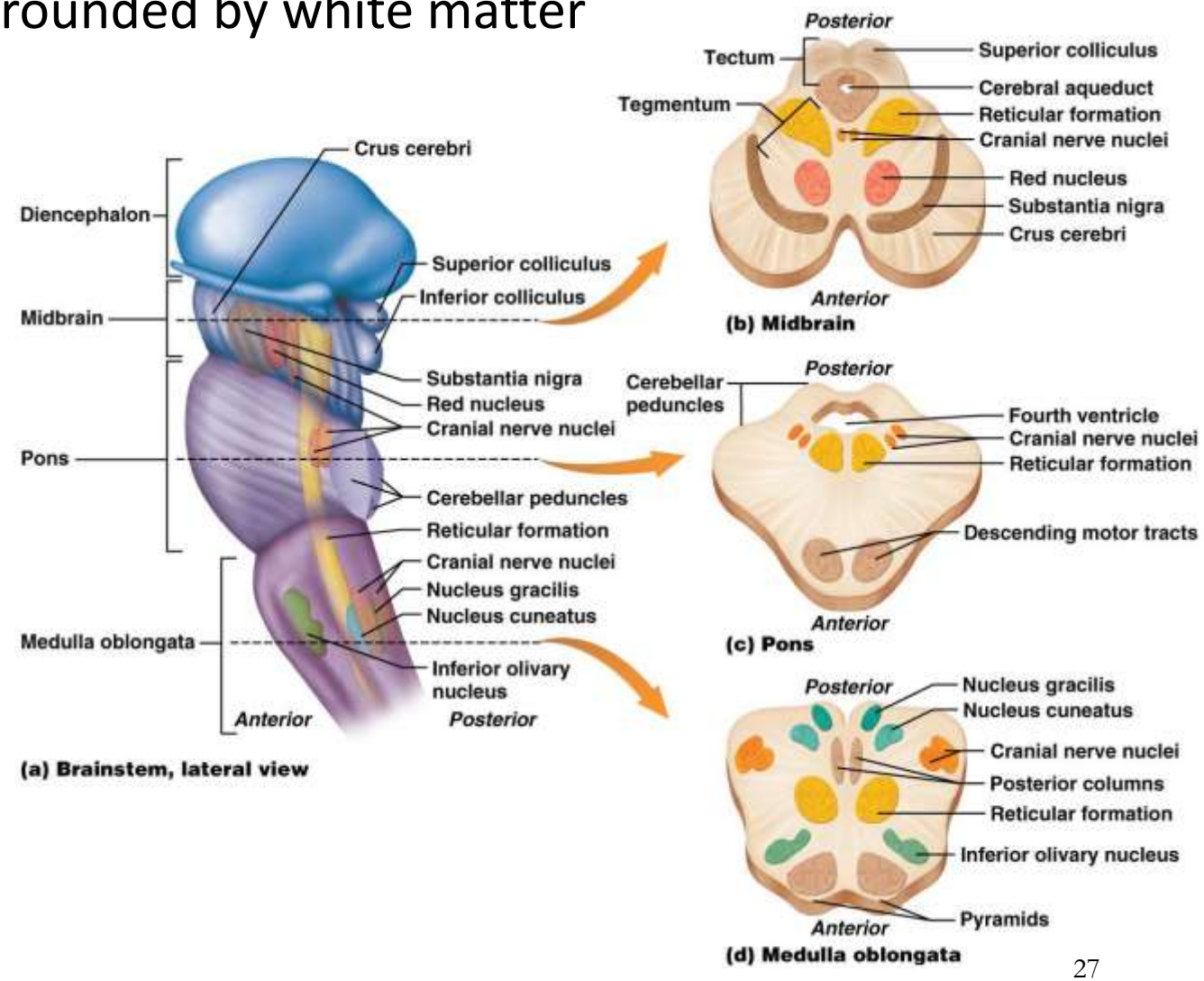

Midbrain

- Between the diencephalon & pons
  - Contains the cerebral aqueduct.

1. **Corpora quadrigemina:** two paired projections at the posterior surface of brainstem
   - *Superior colliculi* (visual reflexes)
   - *Inferior colliculi* (auditory reflexes)

2. **Cerebral peduncles:**
   - Two ventral bulges that hold up the cerebrum
   - **Substantia Nigra:**
     - Dark, band-like pigmented region
     - Works with basal nuclei to control movement
   - **Red nucleus:**
     - Posterior to substantia nigra
     - Communicates with cerebellum and other regions to regulate movement.

Pons

- Bulging region between the midbrain and medulla oblongata
- Middle cerebellar peduncles – attaches the cerebellum to the brainstem
- Regulation of *breathing* with the medulla oblongata

Medulla Oblongata

- Inferior portion of the brain stem
  - Continuous with spinal cord at foramen magnum
- Autonomic reflex center
  - Cardiovascular center – HR & BP
  - Respiratory center – BR & depth
  - Vomiting, Hiccupping, Swallowing, Coughing

Reticular Formation

- Loose cluster of nuclei at the core of **brainstem**
  - Project through brainstem and cerebrum
    - Maintains consciousness and alertness
    - Habituation → ability to ignore repetitive stimuli while remaining sensitive to others.

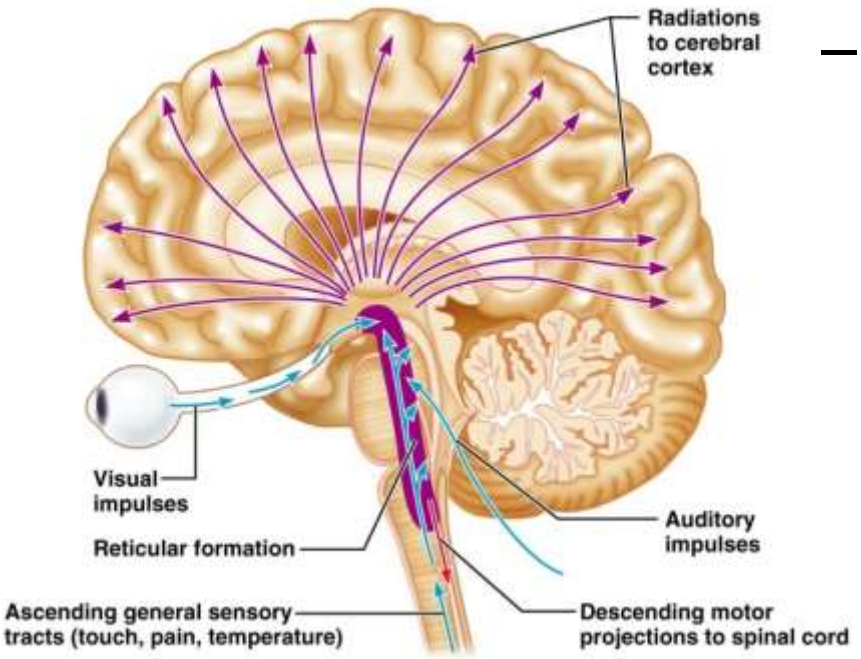

Cerebellum

- Dorsal to the pons & medulla oblongata
  - Exterior ridges called **folia**; separated by shallow sulci
  - Two hemispheres connected by the **vermis**
  - Anterior, poster, and flocculonodular lobes

  - Tissue regions:
    - Gray matter cortex
    - **Arbor vitae**: Internal white matter

  - Fine-tunes and coordinates skeletal muscle movements
  - Helps with posture and equilibrium

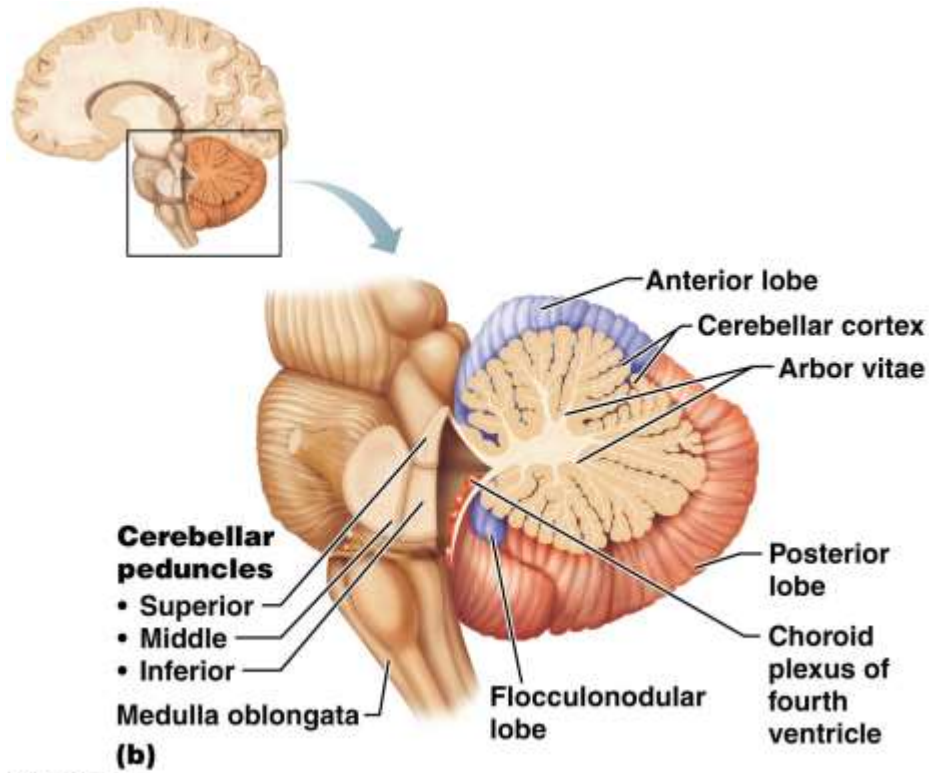

The Spinal Cord

- Enclosed in vertebral column
  - Begins at the foramen magnum
  - Ends at Lumbar$_1$ or L_2 vertebra
  - Provides two-way communication
  - Major reflex center
  - **Conus medullaris:**
    - Inferior region of spinal cord
  - **Cauda equina:**
    - Inferior tail of spinal nerves

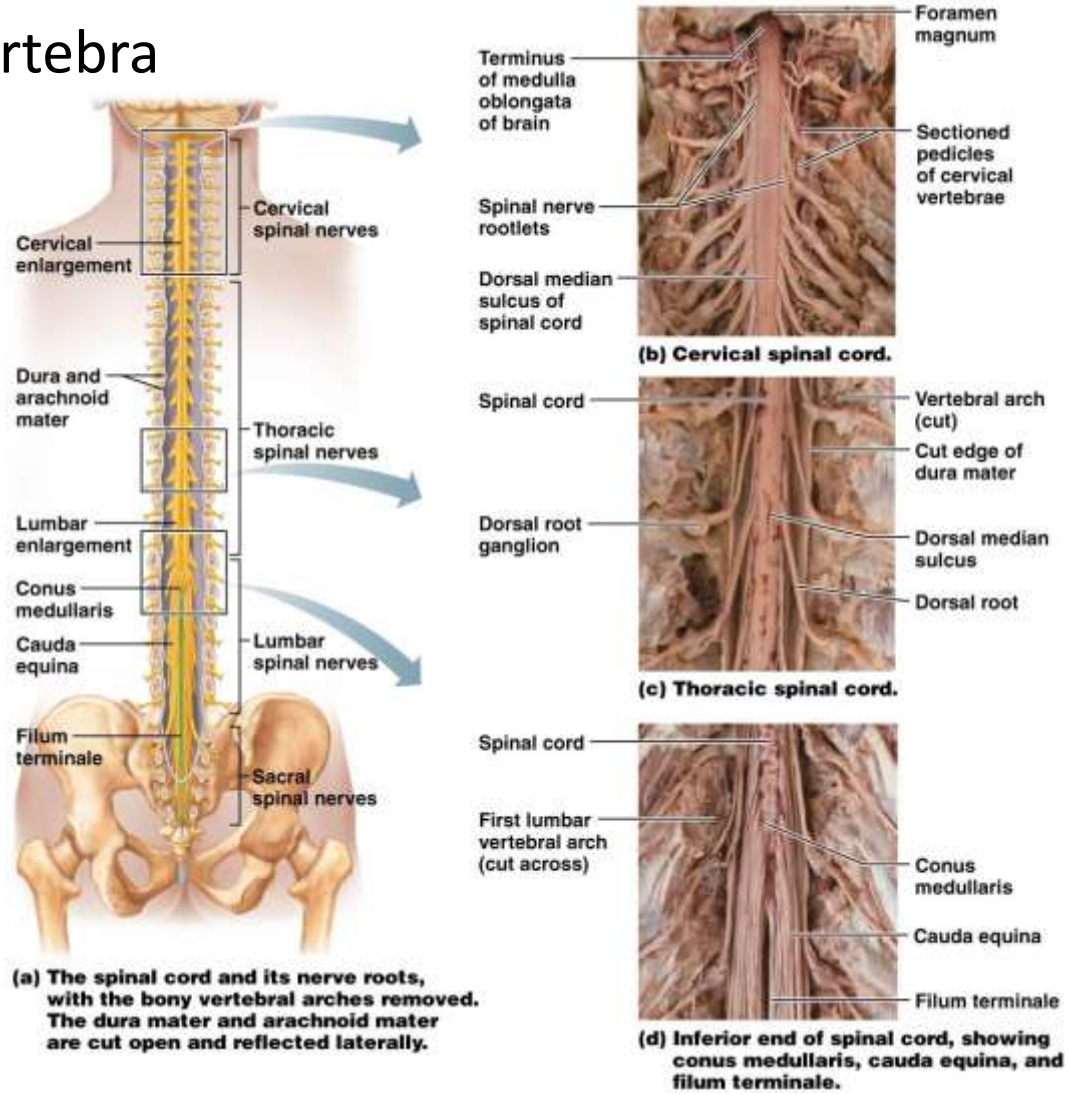

(a) The spinal cord and its nerve roots, with the bony vertebral arches removed. The dura mater and arachnoid mater are cut open and reflected laterally.

(b) Cervical spinal cord.

(c) Thoracic spinal cord.

(d) Inferior end of spinal cord, showing conus medullaris, cauda equina, and filum terminale.

Internal anatomy of spinal cord

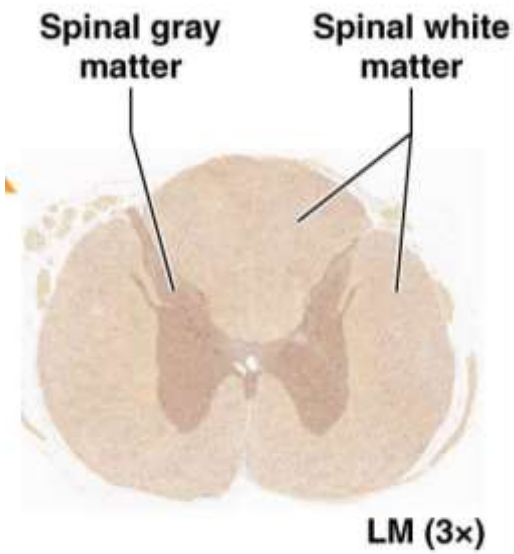

(b) Spinal cord, transverse section

- <u>Tissue</u> regions:
  - Internal **gray matter** → butterfly shape
    - **Gray commissure**: cross bar of the H
    - **Central canal:** Hollow center, filled with CSF
  - External **white matter**
    - Right/Left hemisphere separated by:
      - **ventral median fissure**
      - **dorsal median sulcus**

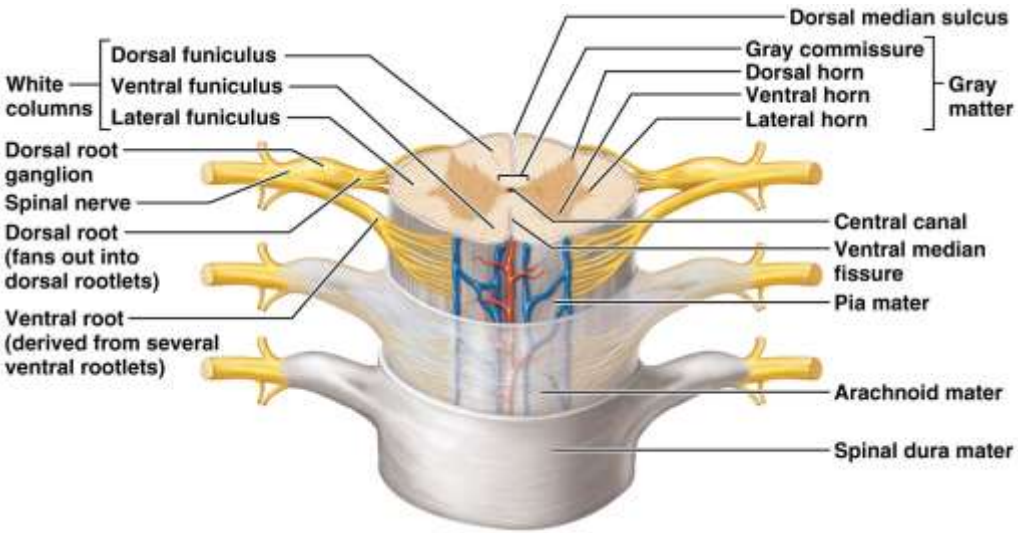

Internal anatomy of spinal cord

- Gray matter divided into four horns based on innervation
  1. **Anterior gray horn** – somatic motor nuclei (SM)
  2. **Lateral gray horn**– visceral motor nuclei (VM)
  3. **Posterior gray horn** –visceral (VS) & somatic (SS) sensory nuclei

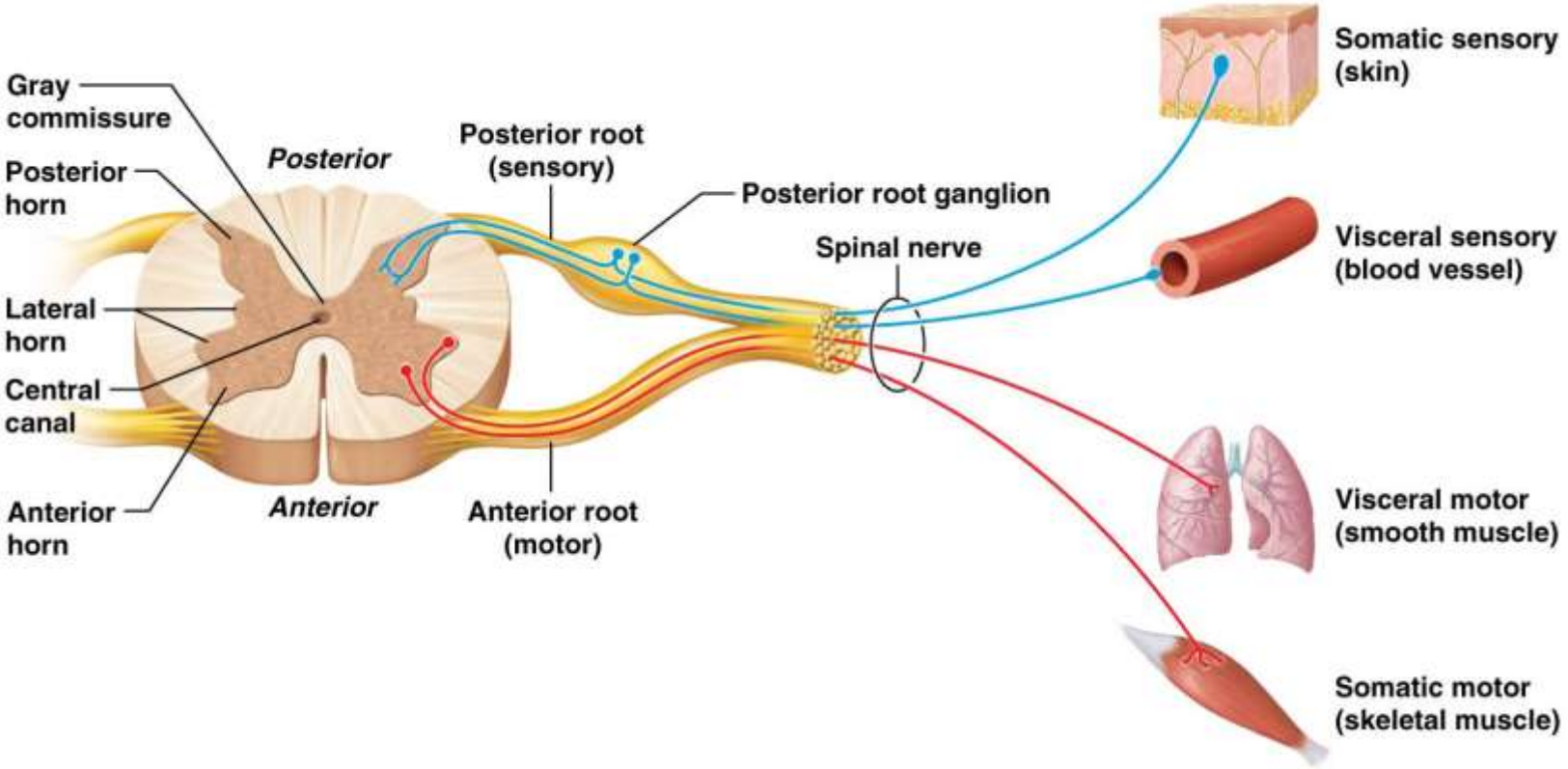

Internal anatomy of spinal cord

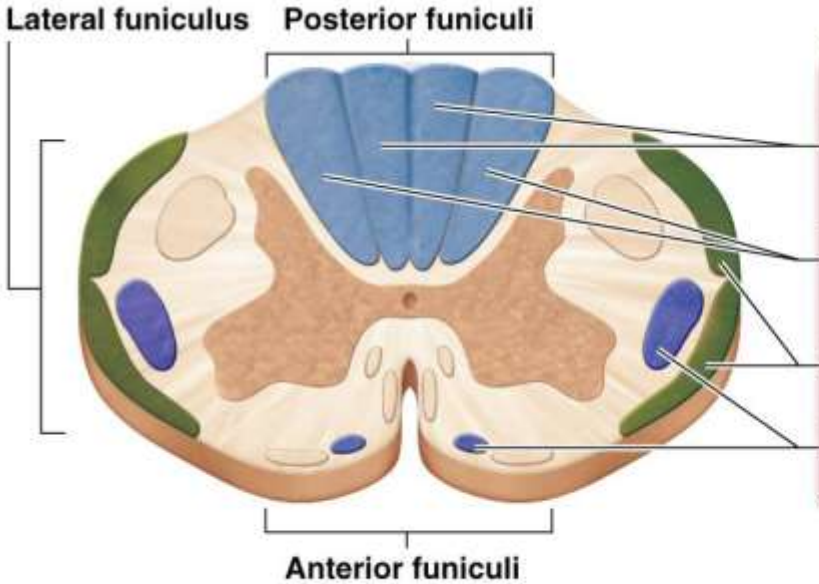

ASCENDING TRACT	FUNCTION
Posterior columns—fasciculus gracilis	• Carry somatosensory information including fine touch, vibration, and proprioception from the lower limbs
Posterior columns—fasciculus cuneatus	• Carry somatosensory information including fine touch, vibration, and proprioception from the trunk, neck, and upper limbs
Spinocerebellar tracts	• Carry proprioceptive information to the cerebellum
Anterolateral system—spinothalamic tracts	• Carry information about pain, temperature, and certain types of touch

(a) Ascending tracts (sensory)

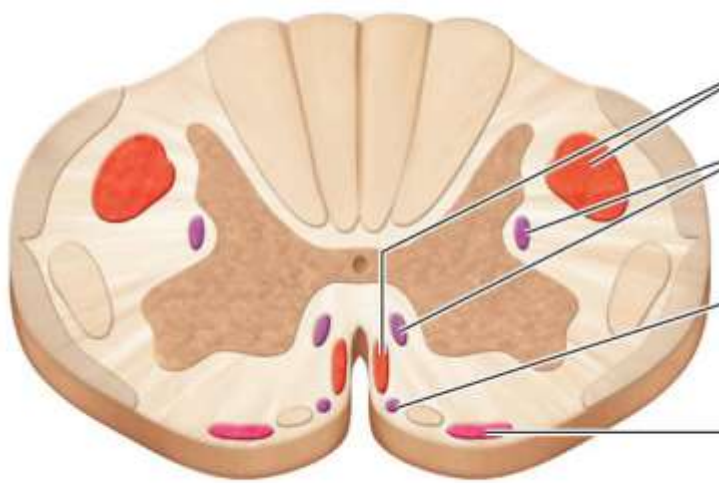

DESCENDING TRACT	FUNCTION
Corticospinal tracts	• Carry motor information from the motor areas of the cerebral cortex
Reticulospinal tracts	• Carry motor information from the brainstem • Important for the maintenance of posture and proper orientation of the limbs during movement
Tectospinal tract	• Carries motor information from the superior colliculus of the brainstem • Important for reflexive movement of the head and eyes
Vestibulospinal tract	• Carries motor information from vestibular nuclei in the brainstem • Important for the maintenance of posture and balance

(b) Descending tracts (motor)

Meninges and CSF Disorders

- **Meningitis**
  - Viral or bacterial infection
  - Causing an inflammation of the meningeal membranes
  - Causes brain or spinal cord inflammation

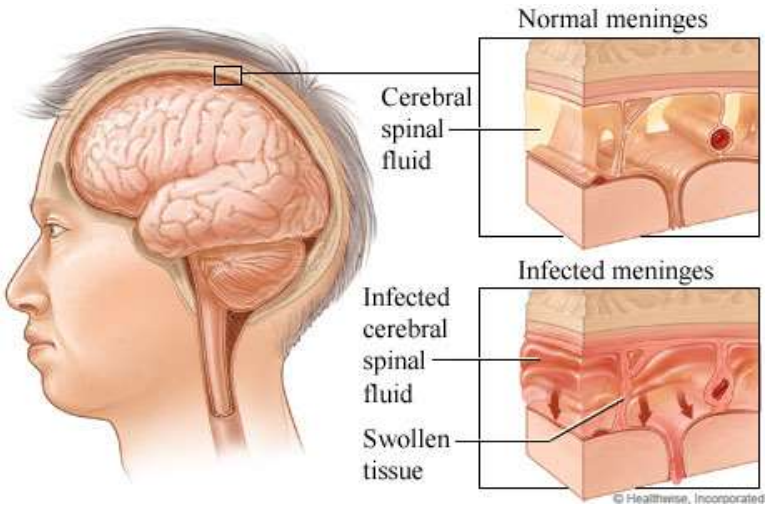

- **Hydrocephalus**
  - "Water on the brain"
  - CSF accumulates and presses on the brain
  - Treated by draining the excess fluid from the ventricles

Brain Disorders

- **Parkinson's Disease**
  - Degeneration of dopamine-releasing neurons of the substantia nigra → basal nuclei are overactive
    - Inhibition of dopamine & motor drive

- **Huntington's Disease**
  - Accumulation of mutant huntingtin protein & degeneration of the basal nuclei and cerebral cortex
    - Overstimulation of motor drive

Nervous system disorders

- **Chronic Traumatic encephalopathy (CTE):**
  - Caused by repetitive mild traumatic brain injury
  - What areas start to deteriorate?
  - What might result?

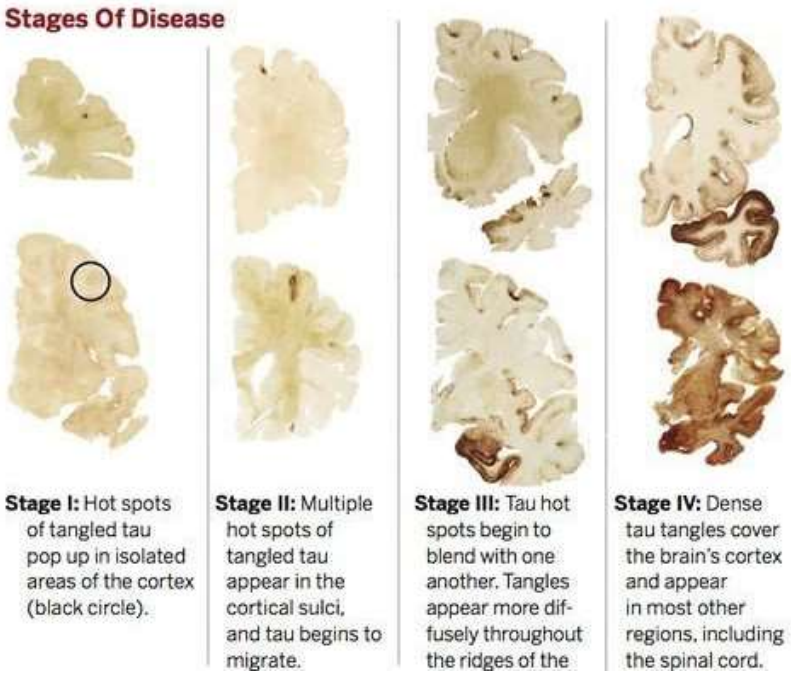

Spinal Cord Injuries

- If spinal cord is severed = communication is gone = loss of sensation and loss of muscle movement = **paralysis**

- Injury in thoracic region = affect lower region of body = **paraplegia**

- Injury in the neck region = affect upper and lower regions of body = **quadriplegia**