PNS – Motor Division

Biology 260
M. Iyengar

Structural organization of the NS

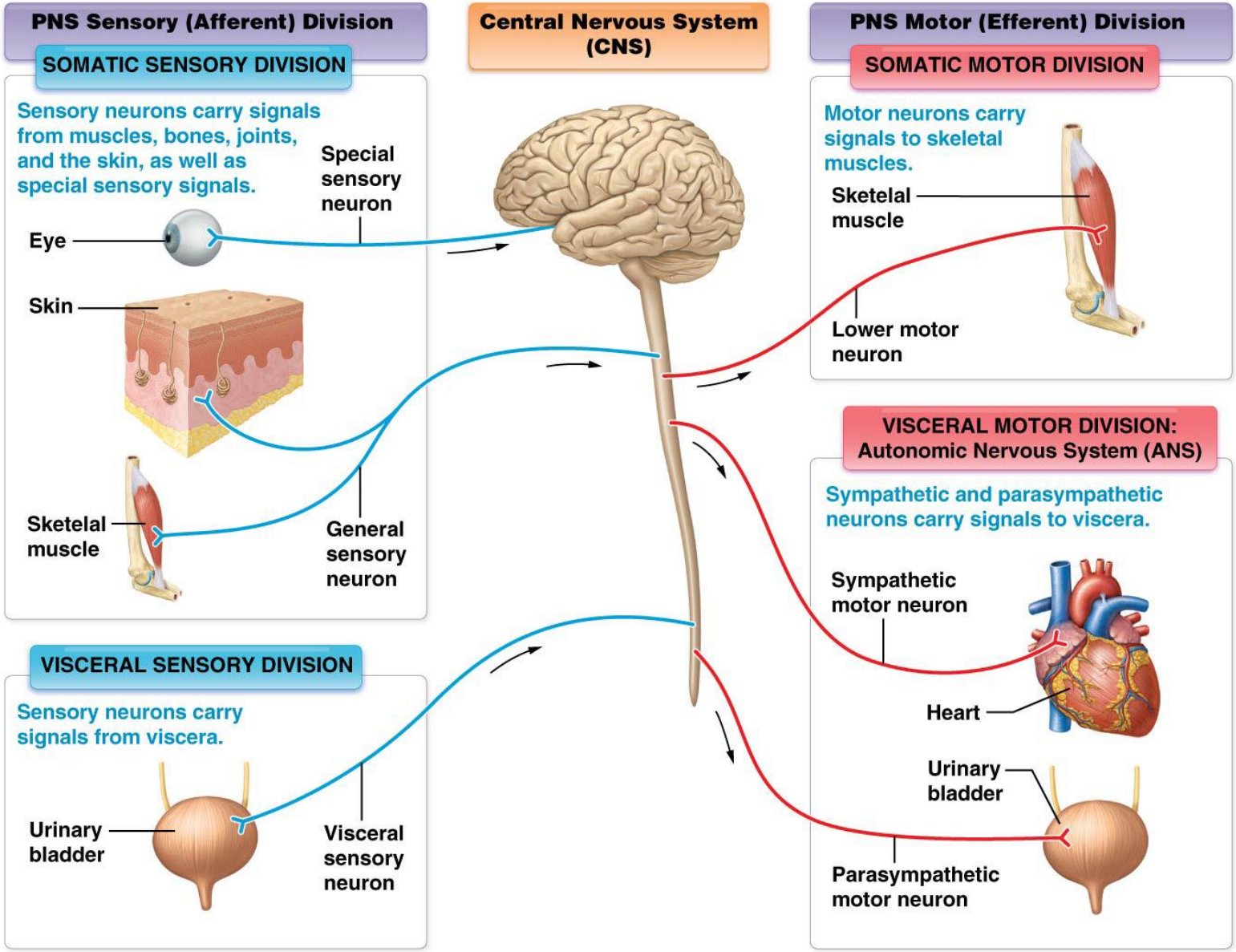

PNS Structures

All the structures outside the brain and spinal cord

Sensory Receptors	*Nerves*	*Motor Endings*

• Monitor and respond to changes in the environment (**stimuli**)
 	
Stimulus
• Five senses
• Pain
• Temperature
 	
Receptor location
• Exteroceptors
• Interoceptors
• Proprioceptors
 	
Receptor structure
• Special organs
• General senses
  • Free or Encapsulated
	• Bundle of myelinated and nonmyelinated axons enclosed by CT
	 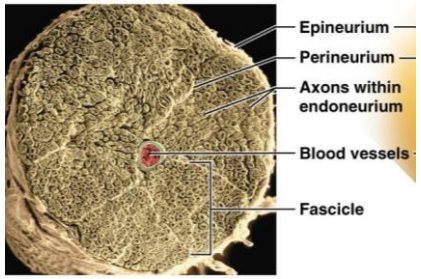
	
	 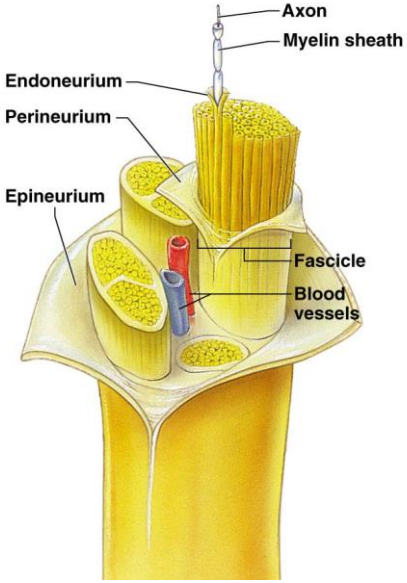
	
		• PNS neurons that activate effectors by releasing neurotransmitters
		• Effector includes:
		  • skeletal muscle, visceral muscle, and glands
		 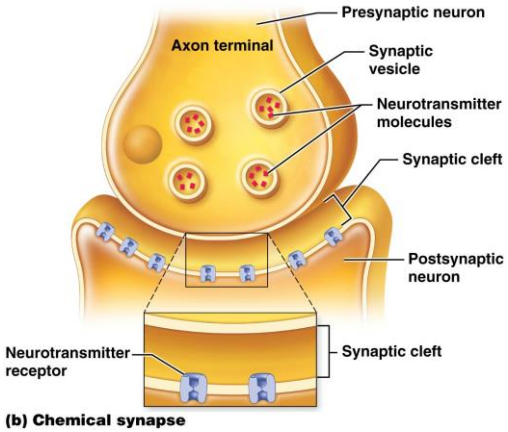

Motor Division

Somatic versus Autonomic

- Voluntary
- Innervate skeletal muscles
- 1 motor neuron system
  - Cell bodies are in the CNS
  - Axons are myelinated, extend from spinal or cranial nerves

- Involuntary
- Innervate cardiac & smooth muscles, and glands
- 2 motor neuron system
  - *Preganglionic* (in CNS)
    - Cell body in the CNS
    - Axon towards an autonomic ganglion
  - *Postganglionic* (in PNS)
    - Axon extends towards the organ

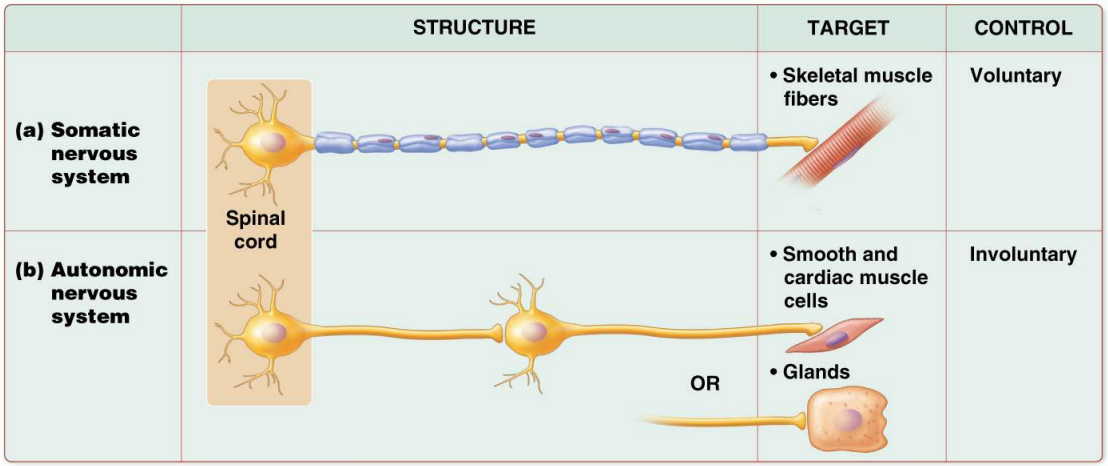

The Big Picture

Control of Somatic Movement by the Nervous System

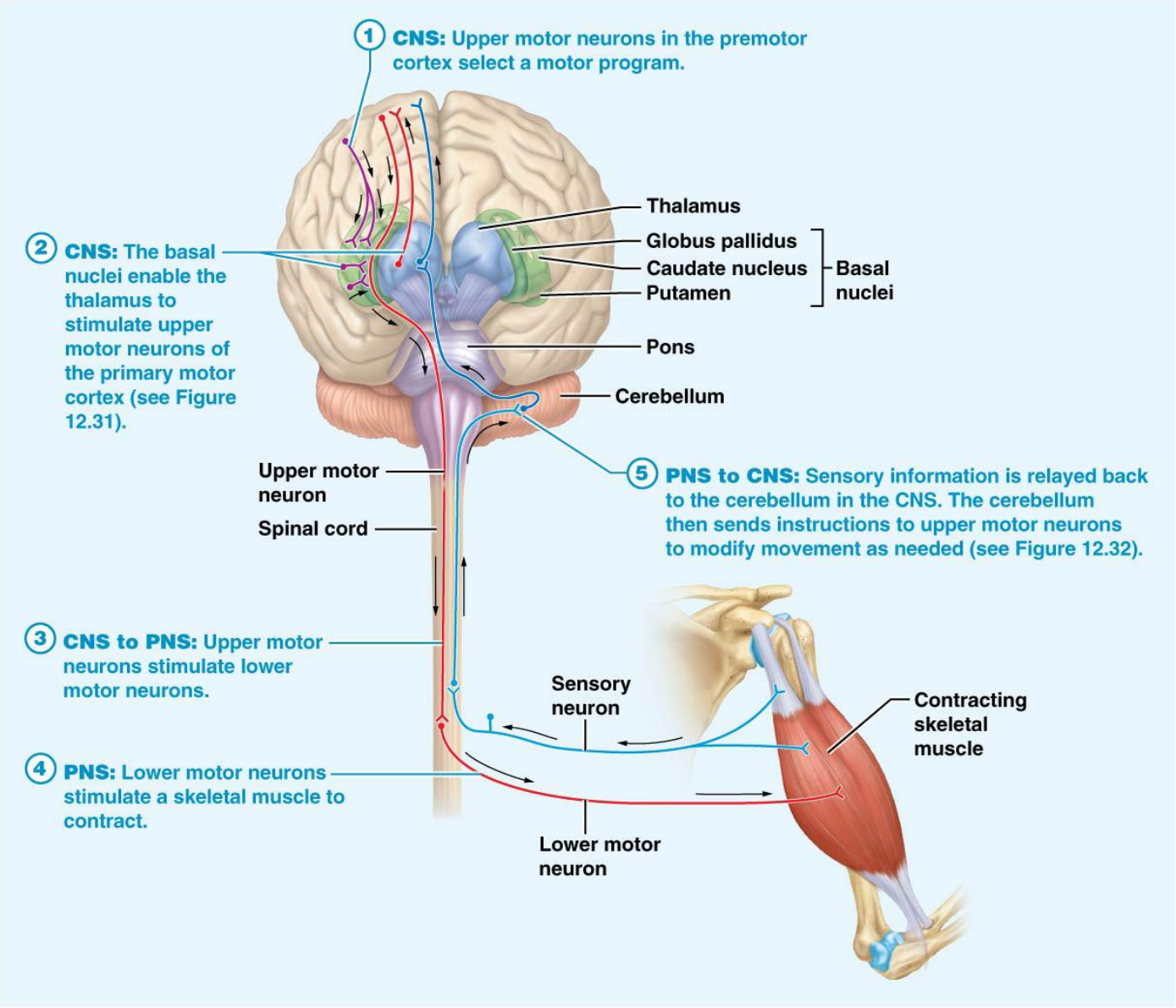

The Big Picture

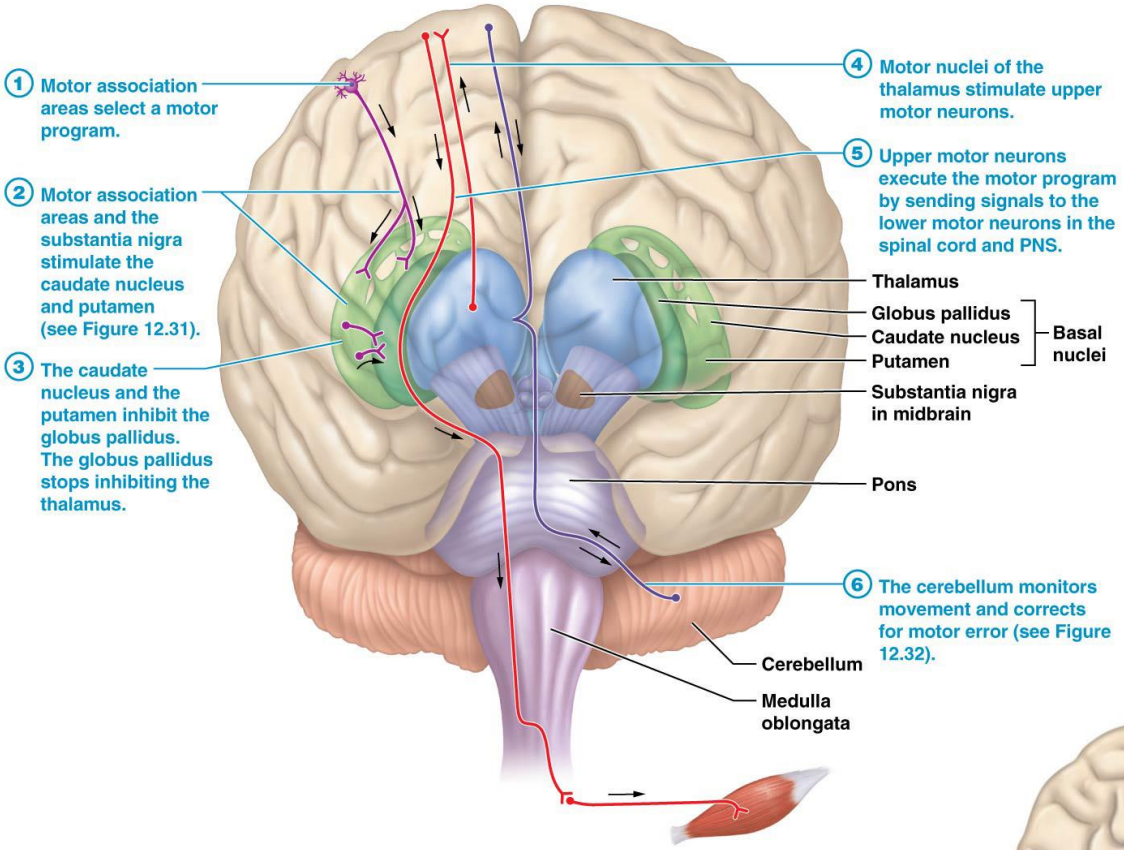

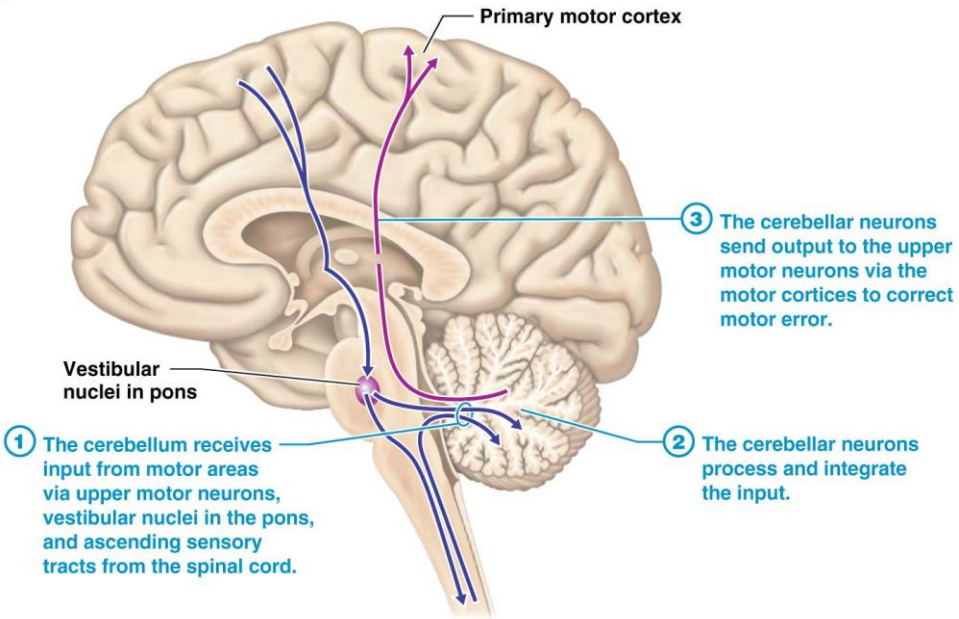

ANS

- **Dual innervation**: all visceral organs are served by both divisions,
  - Two divisions cause opposite effects to maintain homeostasis

1. **Parasympathetic (Rest/Digest)** → Paradise
2. **Sympathetic (Fight/Flight)** → Sympathy for those under stress

Divisions of ANS

Parasympathetic

- Keeps body energy use as low as possible, even while carrying out maintenance activities
  - **REST/DIGEST**
- Directs digestion, urination, defecation
- Example: person relaxing
  - BR, BP, HR, and BV lower
  - Digestion increase
  - Pupils constrict to lower light levels entering the eye

Sympathetic

- Mobilizes body during activity
  - **FIGHT/FLIGHT**
- Exercise, excitement, emergency, embarrassment
- Example: person is running
  - BR, BP, HR, and BV increase
  - Digestion decreases
  - Pupils dilate to increase light levels entering the eye
  - Increase blood sugar levels

Anatomical Differences

Division	Anatomical Feature			
	Site of origin	*Preganglion fiber length*	*Postganglion fiber length*	*Location of ganglia*
Parasympathetic	Craniosacral • Brain stem • Sacrum spinal nerves	Long	short	in or near the visceral organ
Sympathetic	Thoracolumbar • Thoracic & lumbar spinal nerves	Short (pass through **white rami communicantes** and enter **sympathetic trunk ganglia)**	long	close to spinal cord via the sympathetic trunk

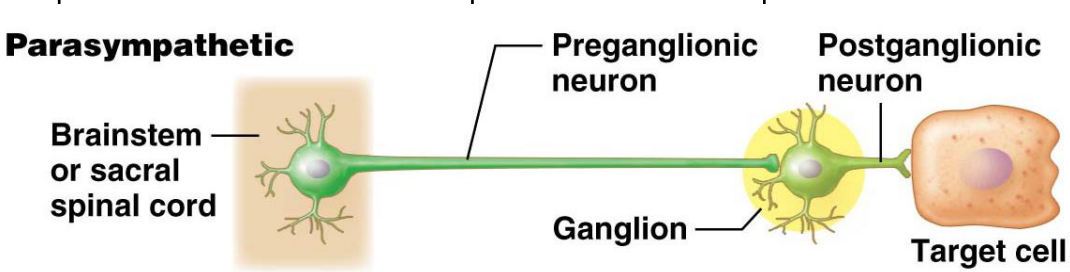

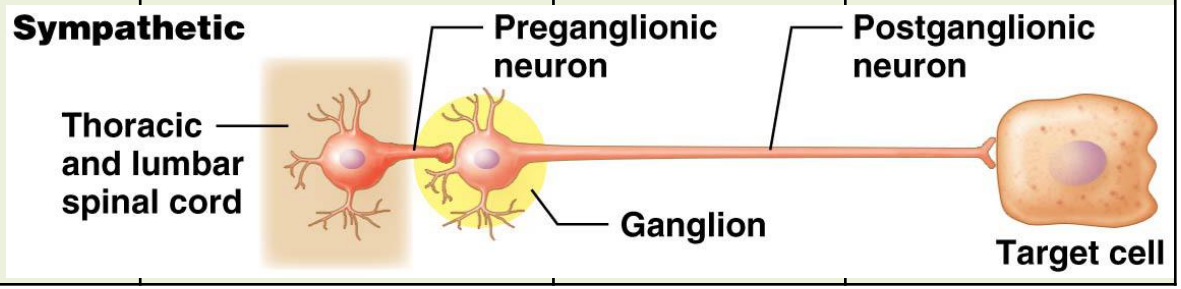

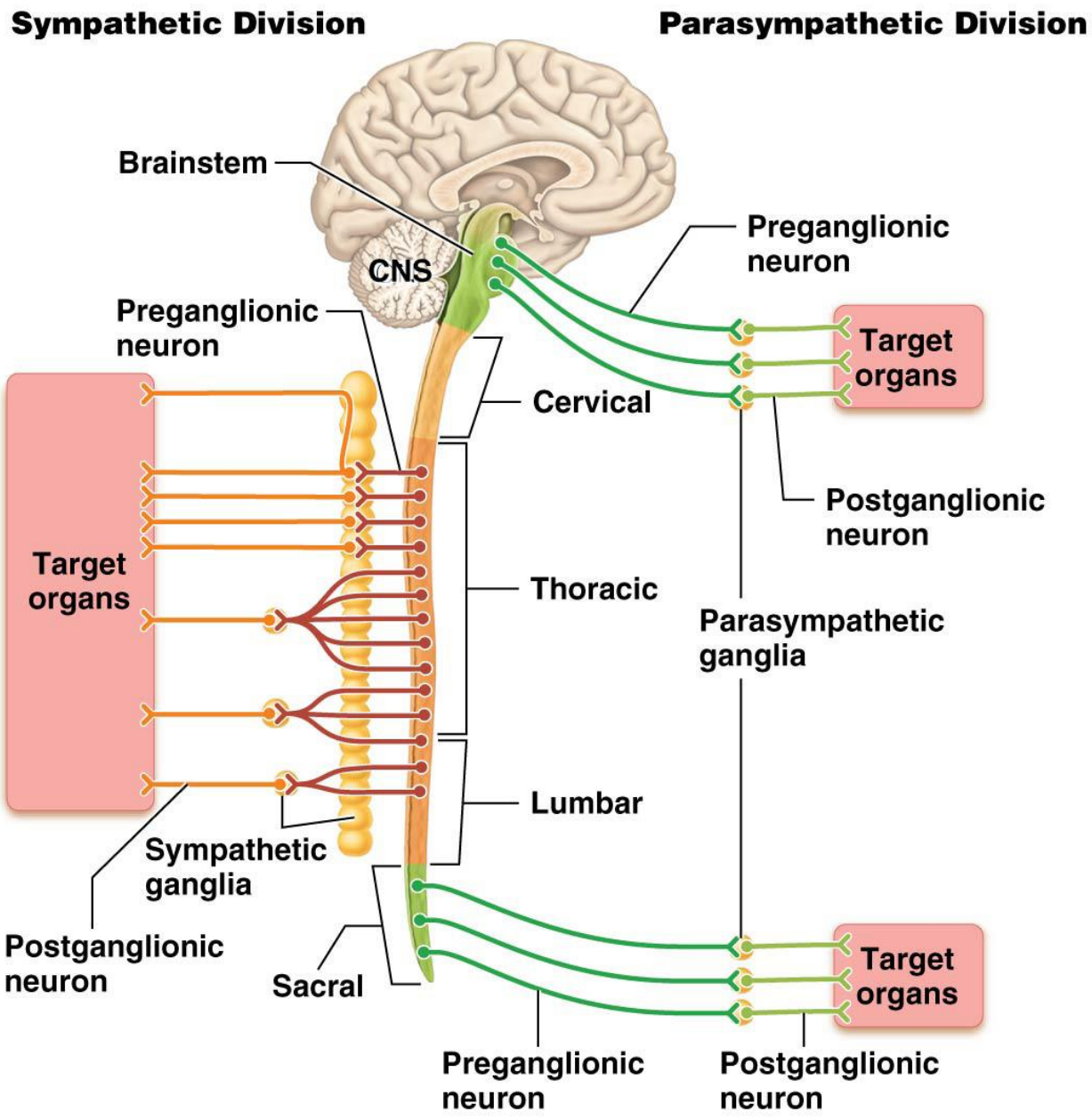
Sympathetic Division
Parasympathetic Division
Brainstem
CNS
Preganglionic neuron
Preganglionic neuron
Target organs
Cervical
Postganglionic neuron
Target organs
Thoracic
Parasympathetic ganglia
Lumbar
Sympathetic ganglia
Postganglionic neuron
Sacral
Target organs
Preganglionic neuron
Postganglionic neuron

Parasympathetic Division

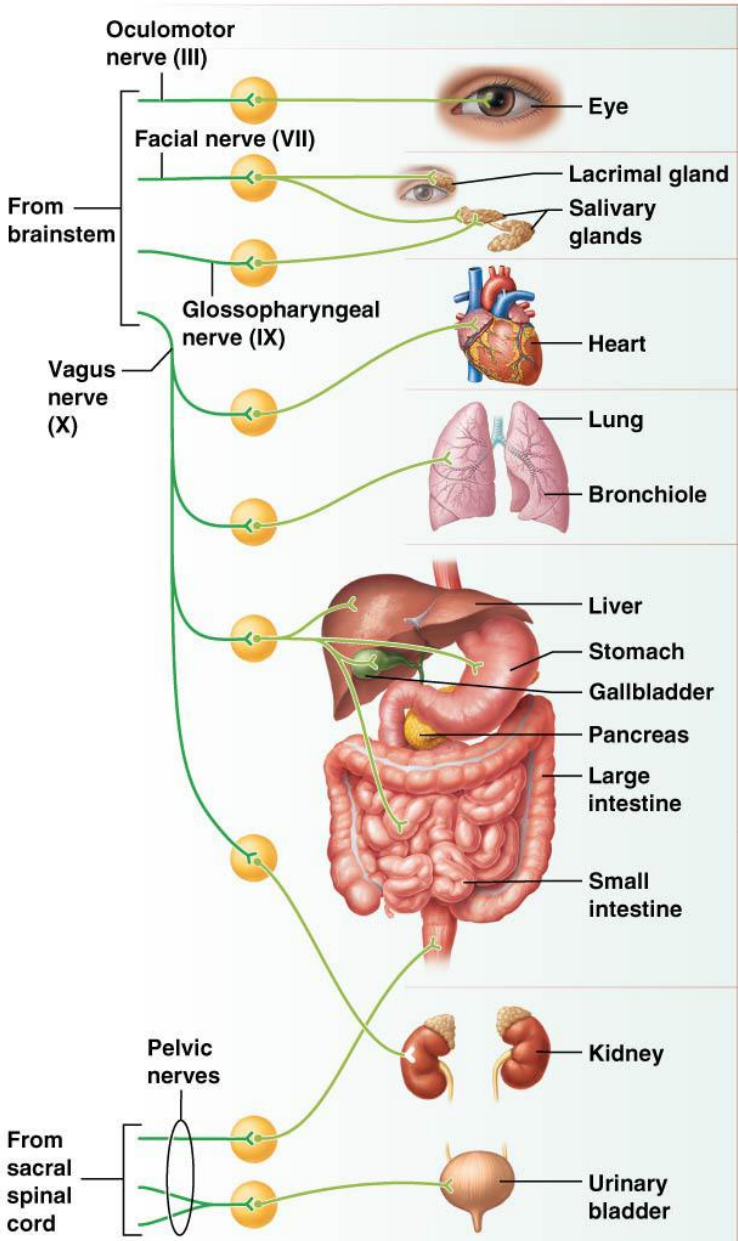

TARGET	MAIN EFFECTS
Smooth muscle cells around pupil and lens	Constriction of pupil, adjustment of lens for near vision
Cells of lacrimal and salivary glands	Increase in secretions
Cardiac muscle cells	Decrease in heart rate
Smooth muscle cells of bronchioles	Bronchoconstriction
Smooth muscle cells of digestive tract and sphincters	Contraction of digestive tract smooth muscle, relaxation of sphincters
Cells of digestive glands	Increase in secretions
Smooth muscle cells of urinary sphincters	Relaxation of sphincters

Sympathetic Division

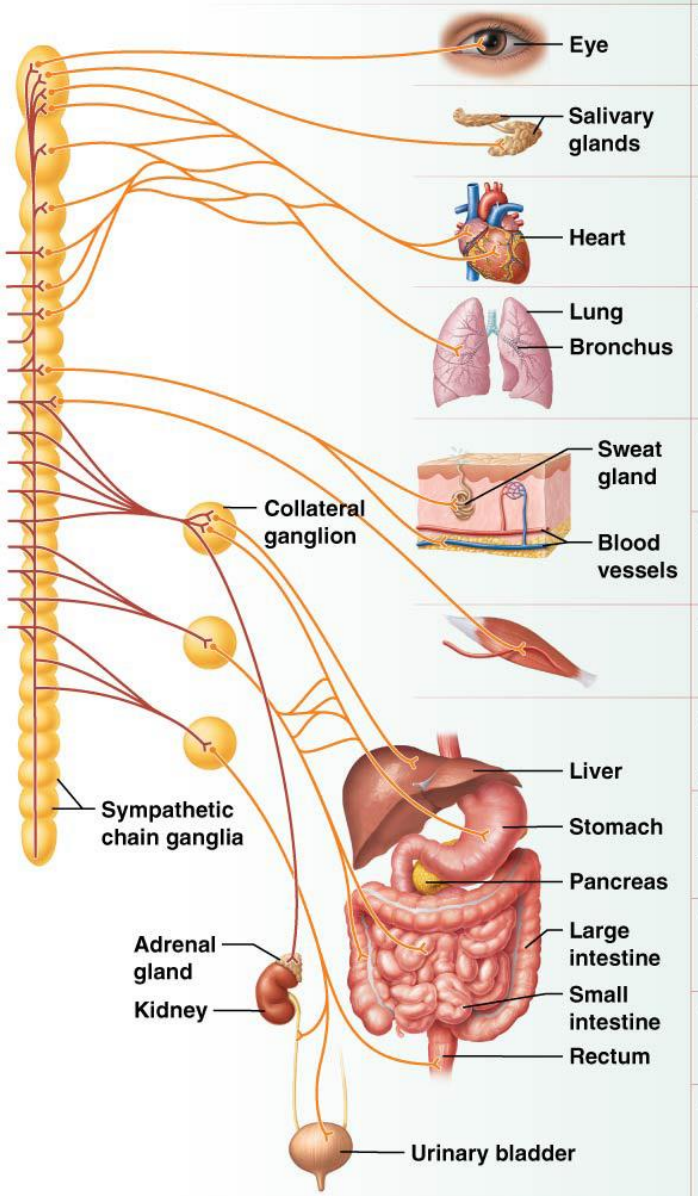

TARGET	NT	RECEPTOR	MAIN EFFECTS
Smooth muscle cells around pupil	NE	α_1	Dilation of pupil
Cells of salivary glands	NE	β_1 and β_2	Increase in secretion in certain cells
Cardiac muscle cells	NE	β_1	Increase in heart rate and force of contraction
Smooth muscle cells of bronchus	NE	β_2	Dilation of bronchioles (bronchodilation)
Cells of sweat glands	ACh	Muscarinic	Increase in secretion
Smooth muscle cells of blood vessels to skin	NE	α_1	Constriction of blood vessels (vasoconstriction)
Smooth muscle cells of blood vessels to skeletal muscles	NE	β_2	Dilation of blood vessels (vasodilation)
Smooth muscle cells of blood vessels to digestive and urinary organs	NE	α_1	Vasoconstriction
Smooth muscle cells of digestive and urinary tracts and sphincters	NE	α_1 (sphincters) β_3 (digestive) β_2 (urinary)	Relaxation of digestive and urinary tracts, contraction of sphincters
Cells of digestive glands	NE	β_2	Decrease in secretion
Cells of pancreas and liver	NE	β_2	Increase in release of glucose
Cells of adrenal medulla	ACh	Nicotinic	Release of epinephrine and norepinephrine

The Big Picture

Functions of the ANS and Visceral Reflex Arcs