Joints

Biology 260
M. Iyengar

Introduction to Joints

- **Joints**, **or articulations** = where two or more bones meet
  - Give skeleton mobility
  - Help hold the skeleton together

- Classified by:

1. **Structure**
   - material that binds the joints and whether a cavity is present

2. **Function**:
   - movement of the joint

Functional Classification of Joints

- **Syn**arthroses: immovable joints
  - Arthro = joint
  - Syn = with or together

- **Amphi**arthroses: slightly movable joints
  - *Amphi* = on both sides, like amphibians→ land and water

- **Di**arthroses: freely movable joints
  - *Dia* = passing through
  - *Di* = two, twice, or double

Structural Classification of Joints

- Fibrous
  - Bones joined by dense fibrous connective tissue
  - Most are immovable, but depends on their length
  - Three types: **Sutures, Syndesmoses,** & **Gomphoses**

- Cartilaginous
  - Bones united by cartilage
  - Not highly movable
  - Two types: **Synchondroses & Symphyses**

- Synovial
  - Bones separated by fluid-filled (synovial) joint cavity
  - All are diarthrotic (freely movable)
  - Include almost all limb joints
  - Have specific characteristics

Fibrous Joints

	SUTURES	SYNDESMOSES	GOMPHOSES
Description	Rigid, interlocking joints of skull	Bones connected by ligaments, bands of fibrous tissue	Peg-in-socket joints
More Info	Contain short connective tissue fibers that allow for expansion but NO movement	Fiber length varies, so movement varies • Short fibers offer little to no movement • Longer fibers offer a larger amount of movement	Fibrous connection is the periodontal ligament
Examples	Between skull bones	Hold tibia and fibula together Hold the radius and ulna together	Only examples are the teeth in alveolar sockets
Helpful tips		Syn = DES, think	

(a) Suture

Joint held together with very short, interconnecting fibers, and bone edges interlock. Found only in the skull.

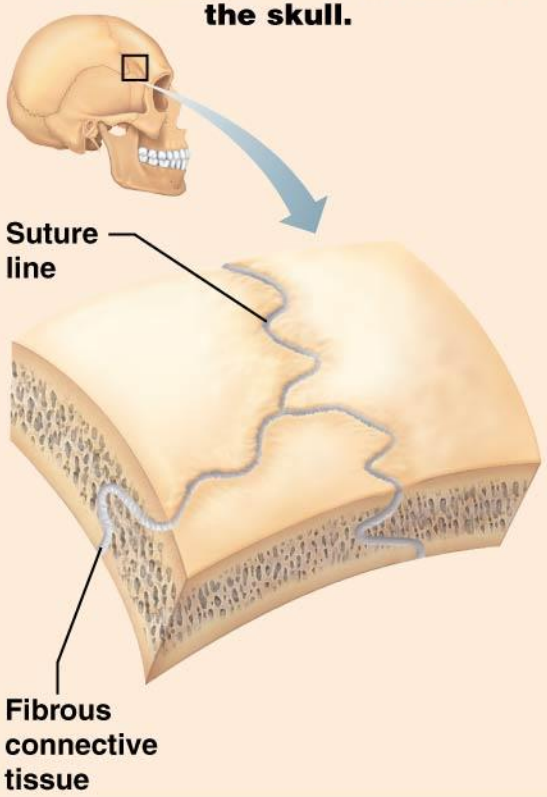

(b) Syndesmosis

Joint held together by a ligament. Fibrous tissue can vary in length, but is longer than in sutures.

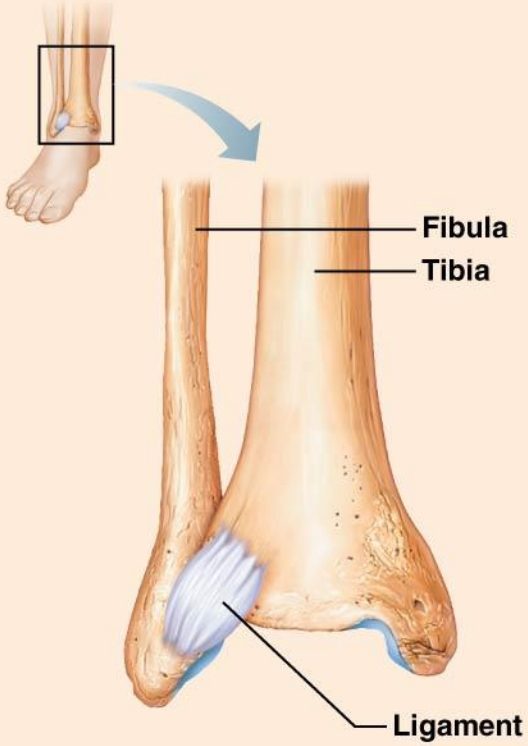

(c) Gomphosis

"Peg in socket" fibrous joint. Periodontal ligament holds tooth in socket.

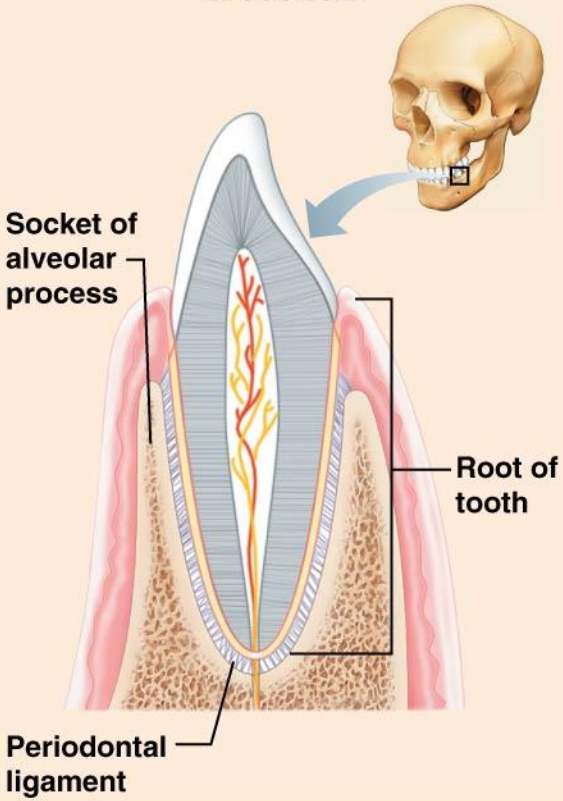

Cartilaginous Joints

	SYNCHONDROSES	SYMPHYSES
Description	• Bar or plate of hyaline cartilage that unites bones • Hyaline cartilage as articular cartilage on bony surfaces	• Fibrocartilage unites bone in **symphysis** joint
More Info	Almost all are synarthrotic (immovable)	Symphyses are strong, amphiarthrotic (slightly movable) joints
Examples	• Temporary epiphyseal plate joints • Cartilage of 1st rib with manubrium of sternum	• Pubic symphysis • Intervertebral discs
Helpful tips		

(a) Synchondroses

Bones united by hyaline cartilage

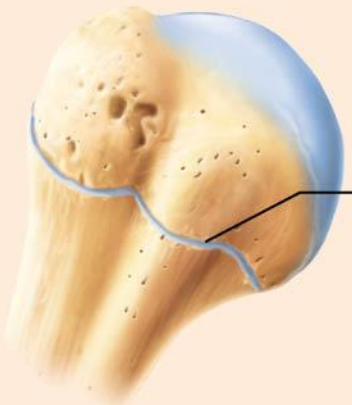

Epiphyseal plate (temporary hyaline cartilage joint)

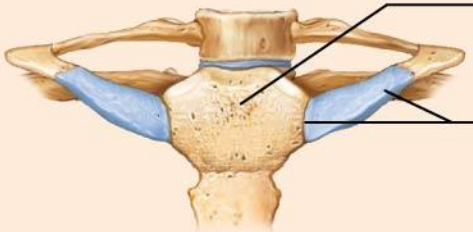

Sternum (manubrium)

Joint between first rib and sternum (immovable)

(b) Symphyses

Bones united by fibrocartilage

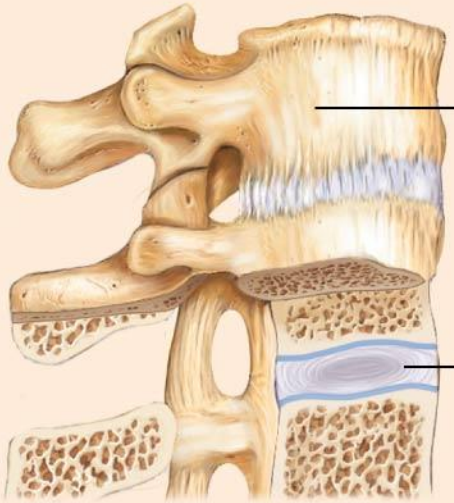

Body of vertebra

Fibrocartilaginous intervertebral disc (sandwiched between hyaline cartilage)

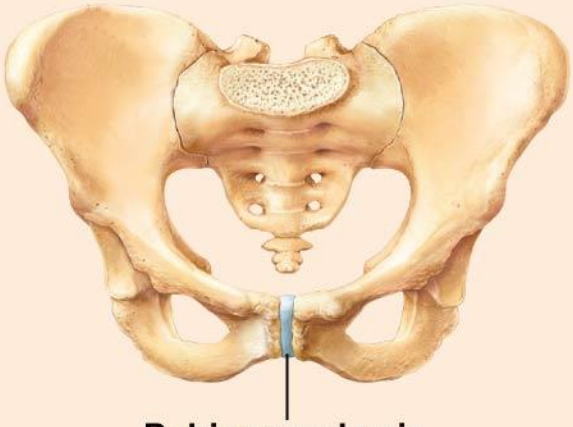

Pubic symphysis

General Structure of Synovial Joints

1. Articular cartilage = hyaline cartilage covering ends of bones

2. Articular (joint) capsule: two layers thick
   - External fibrous layer: dense irregular CT
   - Inner synovial membrane: loose CT → makes synovial fluid

3. Joint (synovial) cavity: small, fluid-filled space

4. Synovial fluid: viscous, slippery fluid
   - Lubricates and nourishes articular cartilage

5. Different types of reinforcing ligaments
   - **Capsular**: thickened part of fibrous layer
   - **Extracapsular** & **Intracapsular**

6. Nerves and blood vessels

General structure of a synovial joint.

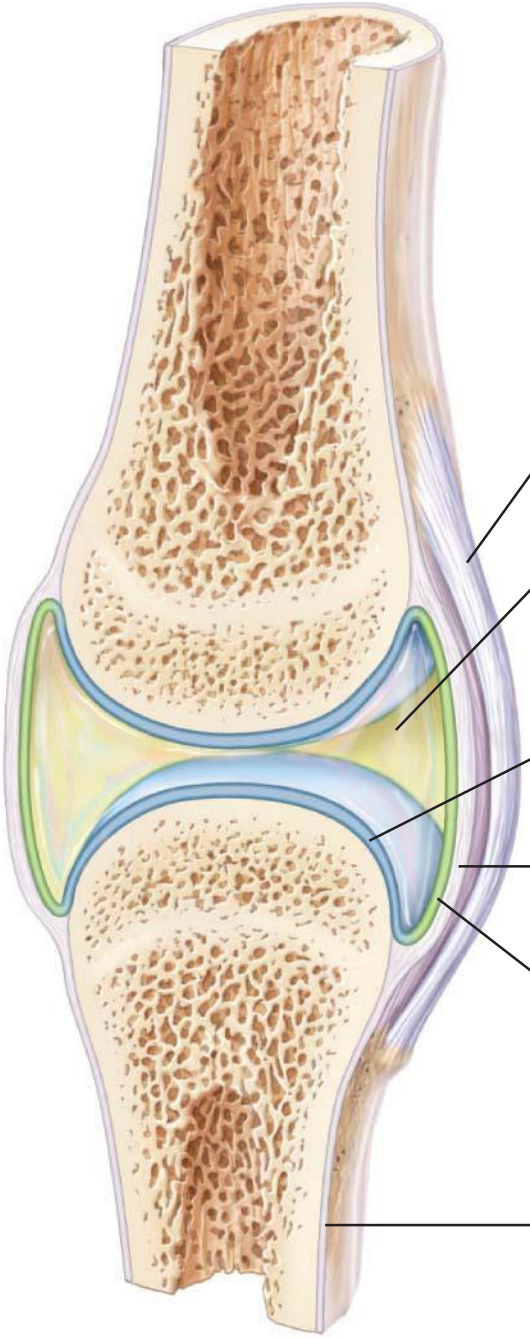

Bursae and Tendon Sheaths of Synovial Joints

- Bags of synovial fluid that act as lubricating "ball bearing"

- **Bursae**: reduce friction where ligaments, muscles, skin, tendons, or bones rub together

- **Tendon sheaths**: elongated bursae wrapped completely around tendons subjected to friction

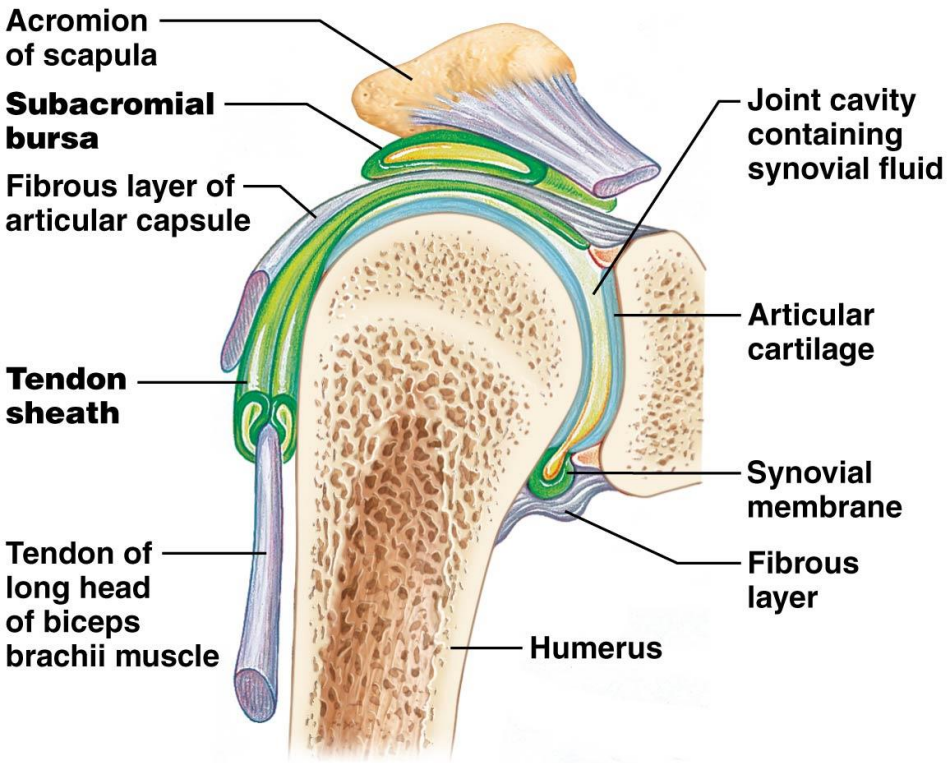

(a) Frontal section through the right shoulder joint

Stability of Synovial Joints

1. Muscle tone keeps tendons taut as they cross joints (most important)
   - Extremely important in reinforcing shoulder and knee joints and arches of the foot

2. Ligament number and location (limited role)
   - The more ligaments, the stronger the joint

3. Shape of articular surface (minor role)
   - Shallow surfaces less stable than ball-and-socket

Movements Allowed by Synovial Joints

- Three general types of movements
  - **Gliding -** One flat bone surface glides or slips over another similar surface
  - **Angular movements -** Increase or decrease angle between two bones
  - **Rotation -** turning of bone around its own long axis, toward midline or away from it

Movements Allowed by Synovial Joints

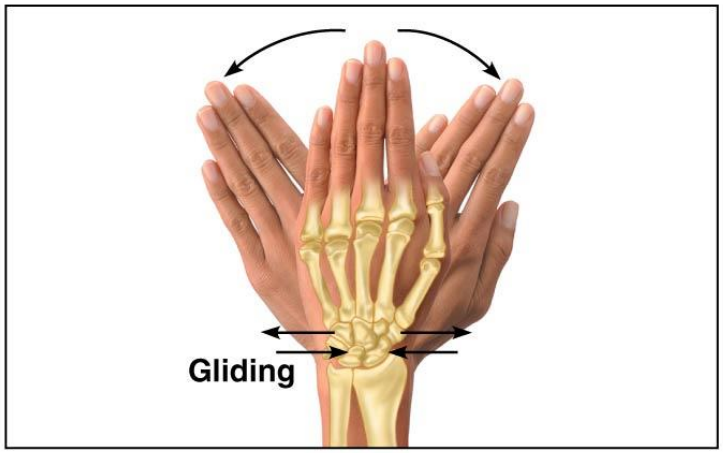

(a) Gliding movements at the wrist

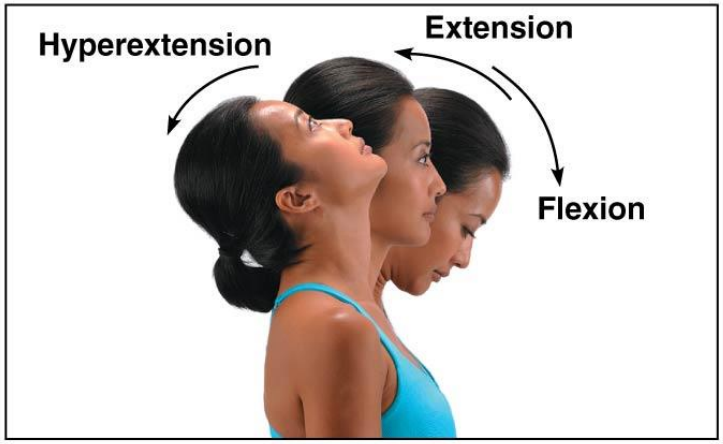

(b) Angular movements: flexion, extension, and hyperextension of the neck

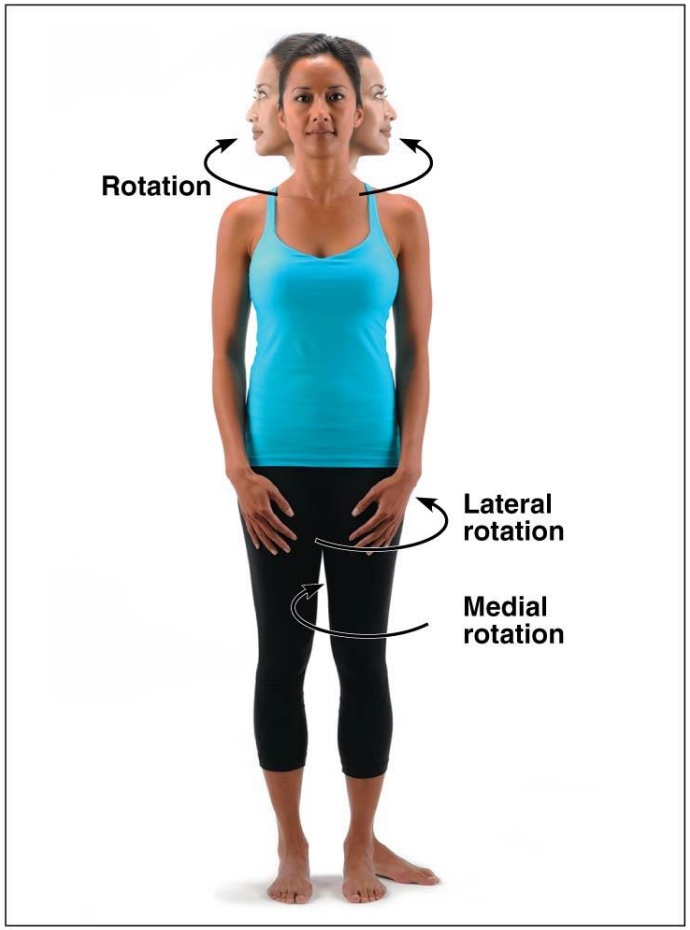

(f) Rotation of the head, neck, and lower limb

Movements Allowed by Synovial Joints

- Angular movements
  - **Flexion**: decreases the angle of the joint
  - **Extension**: increases the angle of the joint
    - **Hyperextension**: movement beyond the anatomical position
  - **Abduction**: movement along frontal plane, away from the midline
  - **Adduction**: movement along frontal plane, toward the midline
  - **Circumduction**
    - Involves flexion, abduction, extension, and adduction of limb

Angular movements

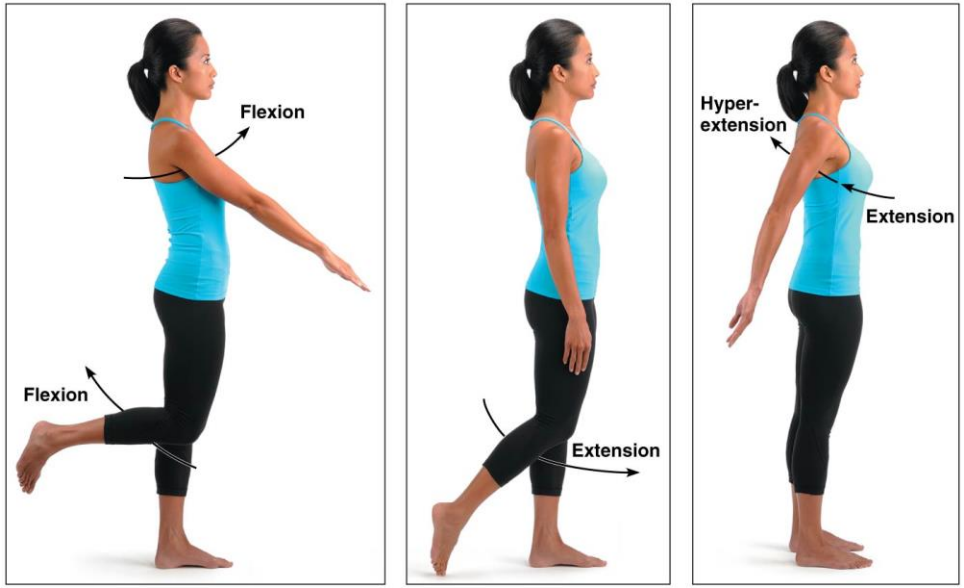

(d) Angular movements: flexion, extension, and hyperextension at the shoulder and knee

(e) Angular movements: abduction, adduction, and circumduction of the upper limb at the shoulder

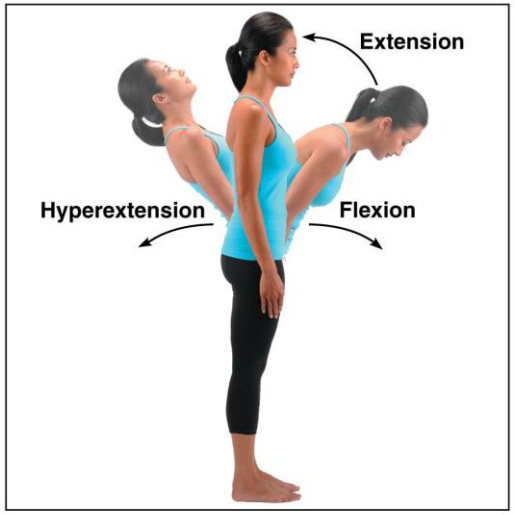

(c) Angular movements: flexion, extension, and hyperextension of the vertebral column

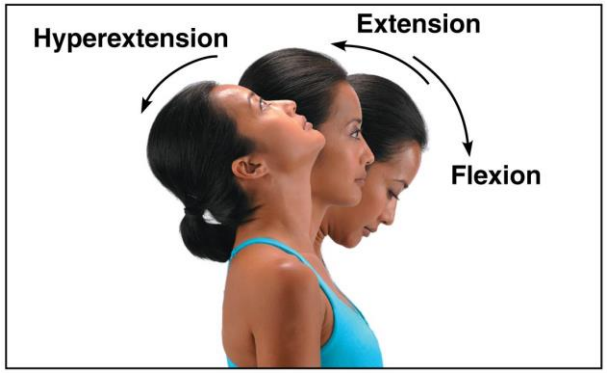

(b) Angular movements: flexion, extension, and hyperextension of the neck

Movements Allowed by Synovial Joints

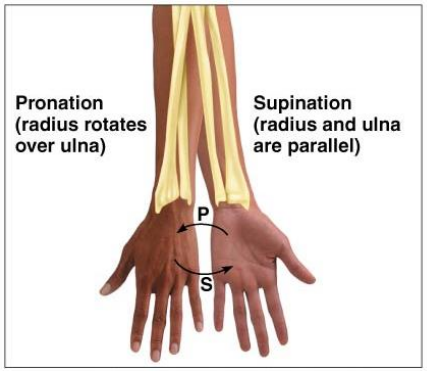

(a) Pronation (P) and supination (S)

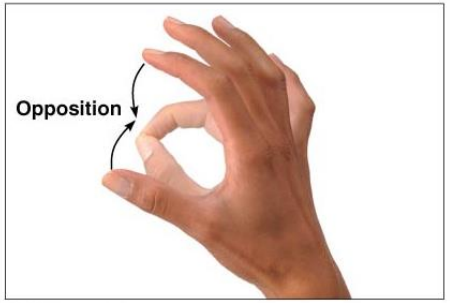

(f) Opposition

(b) Dorsiflexion and plantar flexion

- Special movements
  - **Supination**: palms face anteriorly
    - Radius and ulna are parallel
  - **Pronation**: palms face posteriorly
    - Radius rotates over ulna
  - **Opposition**: movement of thumb
    - Example: touching thumb to tips of other fingers on same hand or any grasping movement
  - **Dorsiflexion**: bending foot toward shin
  - **Plantar flexion**: pointing toes

Movements Allowed by Synovial Joints

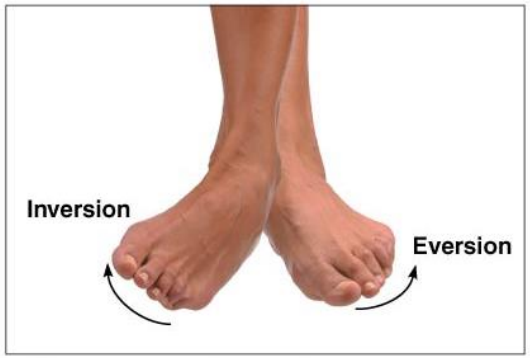

(c) Inversion and eversion

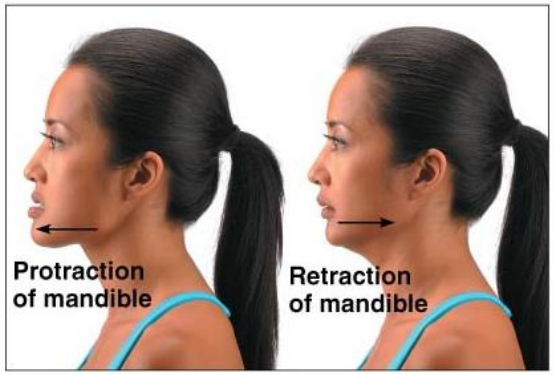

(d) Protraction and retraction

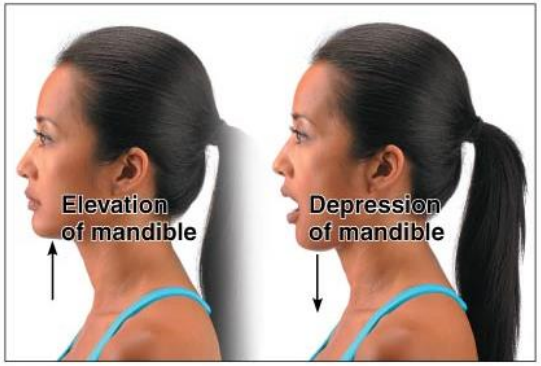

(e) Elevation and depression

- Special movements
  - **Inversion**: sole of foot faces medially
  - **Eversion**: sole of foot faces laterally
  - **Protraction**: mandible juts out
  - **Retraction**: mandible is pulled toward neck
  - **Elevation**: lifting body part superiorly
    - Example: shrugging shoulders
  - **Depression**: lowering body part
    - Example: opening jaw

Types of Synovial Joints

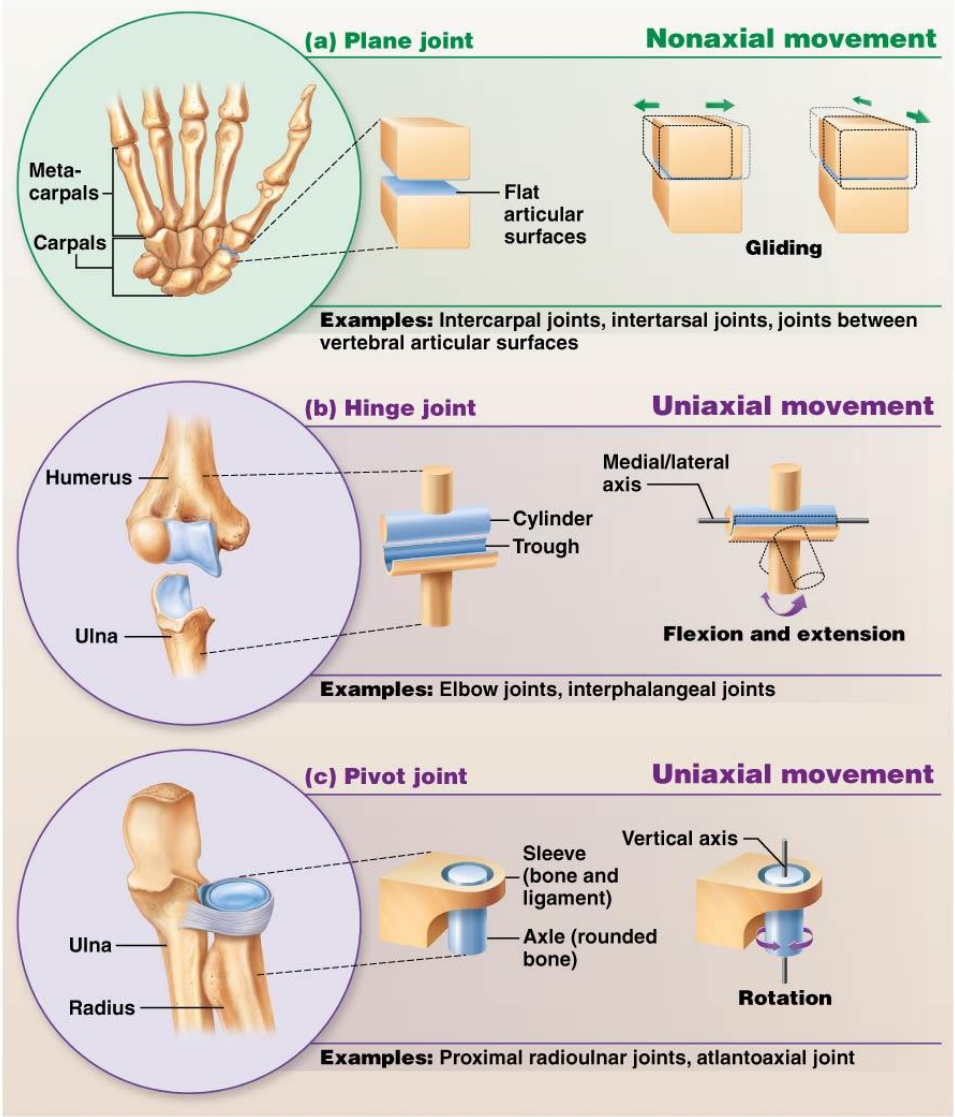

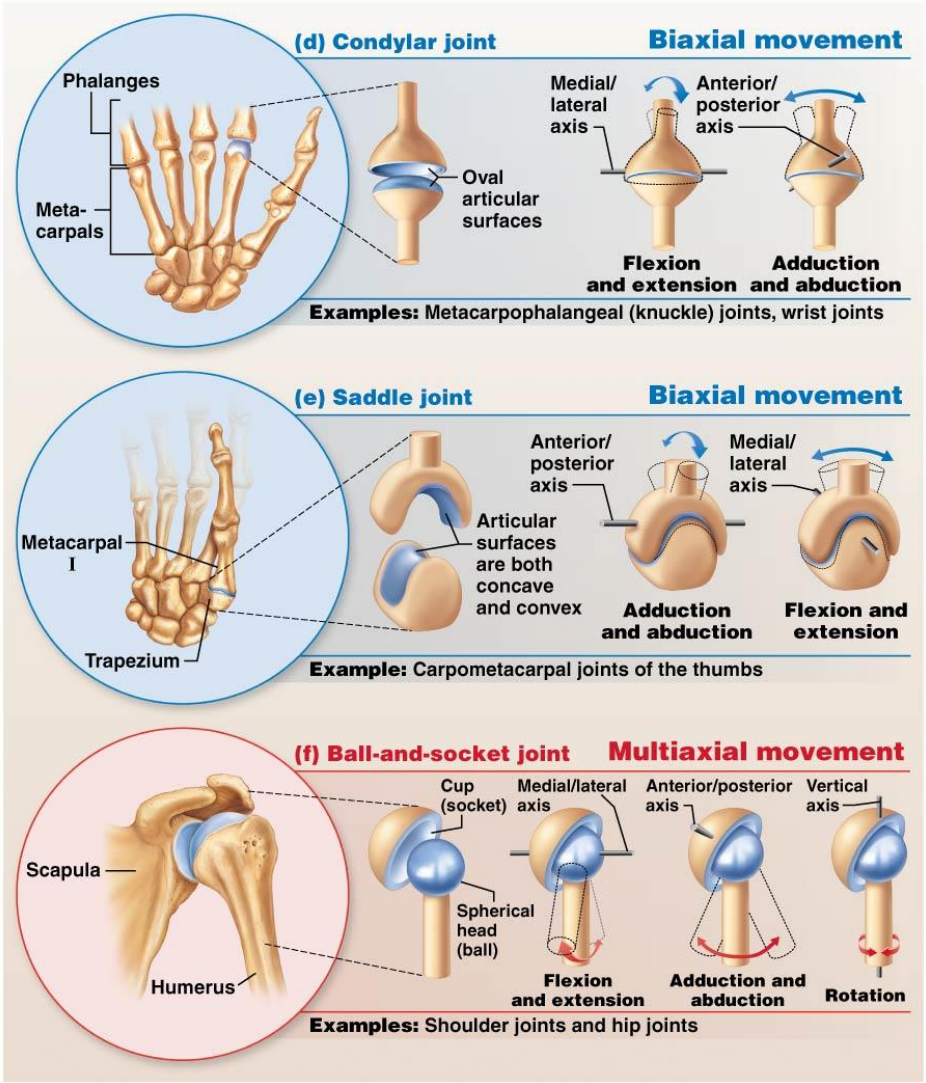

Shoulder Joint

Glenohumeral joint

- connects upper extremity with axial skeleton;
- composed of ball-shaped head of *humerus* and *glenoid cavity* on lateral scapula
- **Glenoid labrum** – *fibrocartilaginous ring*;
  - Increases depth of glenoid cavity to provide more *stability* to this multiaxial joint
- **Biceps brachii tendon** – provides a stabilizing force as it passes over joint; helps keep head of humerus <u>within</u> glenoid cavity
- Tendons of following muscles form **rotator cuff**, providing <u>most</u> of joint's structural stabilization and strength: **supraspinatus**, **infraspinatus**, **subscapularis**, and **teres minor**

Shoulder Joint

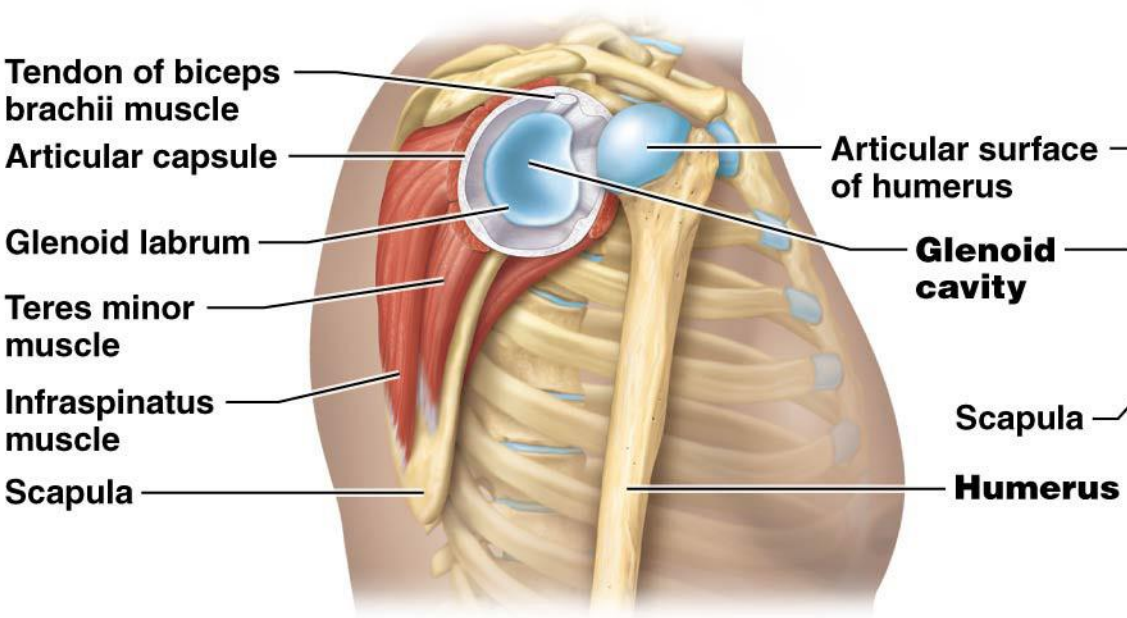

(c) Lateral view with head of humerus removed from glenoid cavity

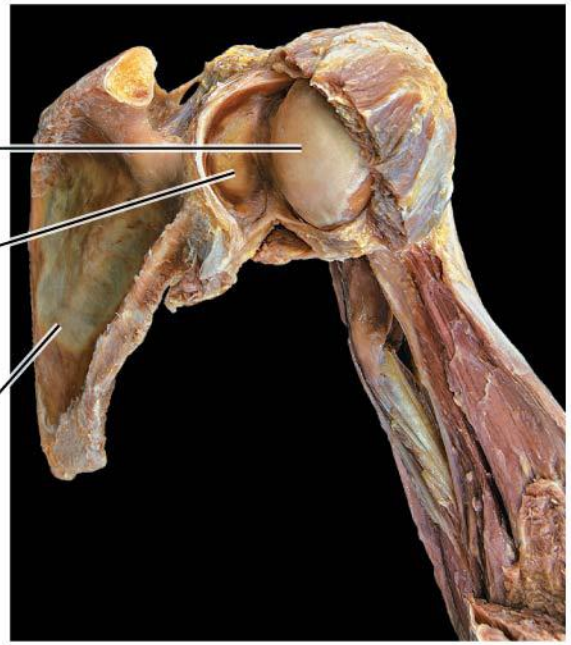

(d) Cadaver photo, lateral view with head of humerus removed from glenoid cavity

Elbow Joints

Stable hinge joint; composed of *two articulations* and *three strong ligaments* that support articular capsule

- **Two joints:**
  - **Humeroulnar joint** –articulation between *trochlea* of humerus and *trochlear notch* of ulna
  - **Humeroradial joint** – articulation between *capitulum* of humerus and *head* of radius

- **Three ligaments joints:**
  - **Radial collateral ligament** (lateral collateral ligament) supports *lateral* side of joint
  - **Ulnar collateral ligament** (medial collateral ligament) supports *medial* side of joint
  - **Anular ligament** binds head of radius to neck of ulna; *stabilizes radial head*

Elbow Joints

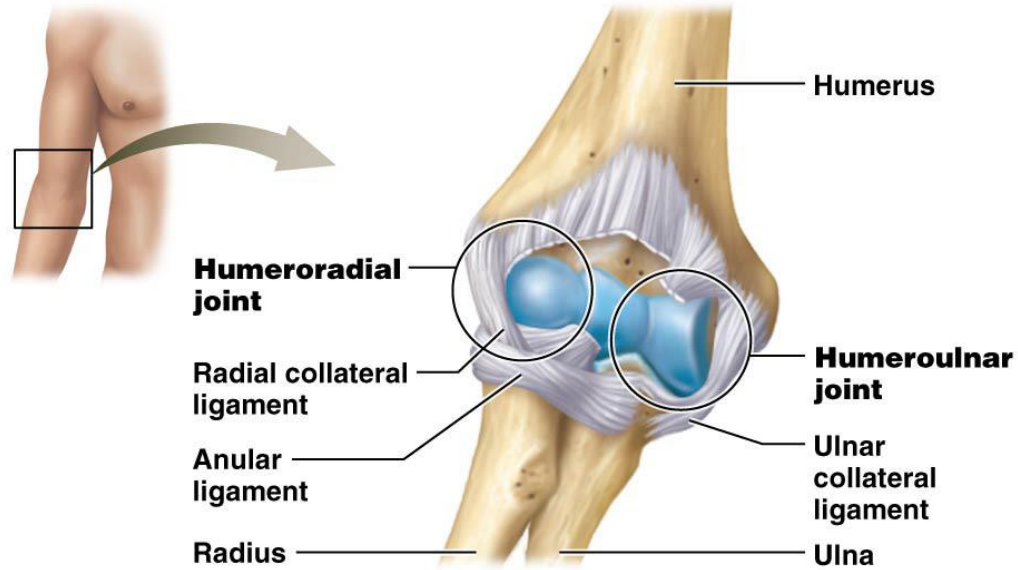

(a) Anterior view

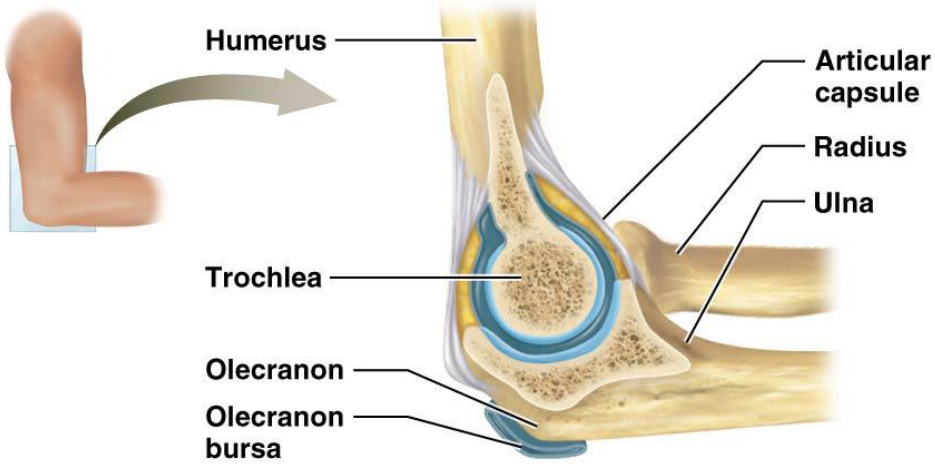

(b) Sagittal view

Hip Joint

- Very stable, multiaxial articulation between *acetabulum* and ball-shaped *head of femur*
  - anatomical features make it stable enough for its weight-bearing responsibilities
  - **Acetabular labrum** – *fibrocartilaginous ring* that helps to stabilize head of femur <u>within</u> acetabulum
  - **Retinacular fibers** – *intracapsular ligaments* that surround neck of femur; reinforce joint capsule
  - **Iliofemoral ligament** – Y-shaped structure that reinforces *anterior* aspect of external joint capsule
  - **Ischiofemoral ligament** – spiral-shaped structure that supports *posterior* joint capsule
  - **Pubofemoral ligament** – triangular-shaped structure that supports *inferior* aspect of joint capsule
  - **Ligament of head of femur** – small ligament that connects head of femur with acetabulum; provides a pathway for small blood vessels servicing femoral head

Hip Joint

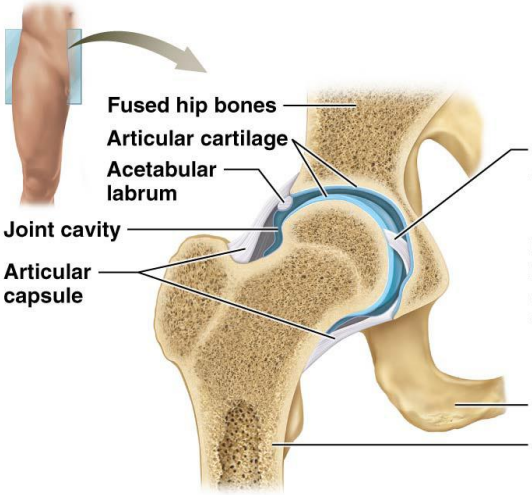

(a) Frontal section, anterior view

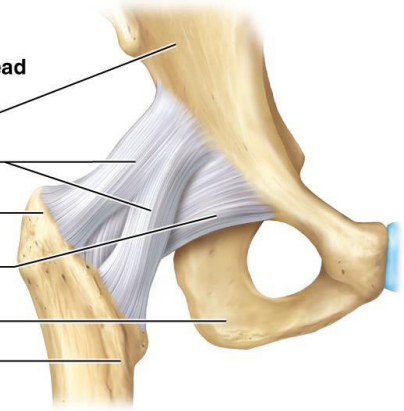

(b) Anterior view

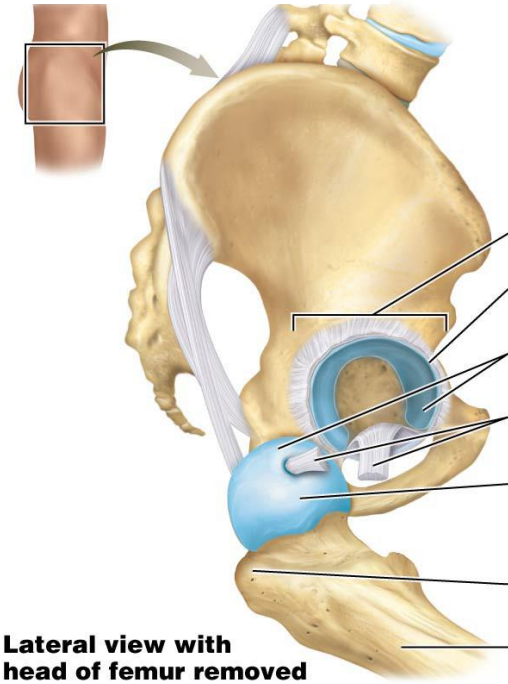

(c) Lateral view with head of femur removed from acetabulum

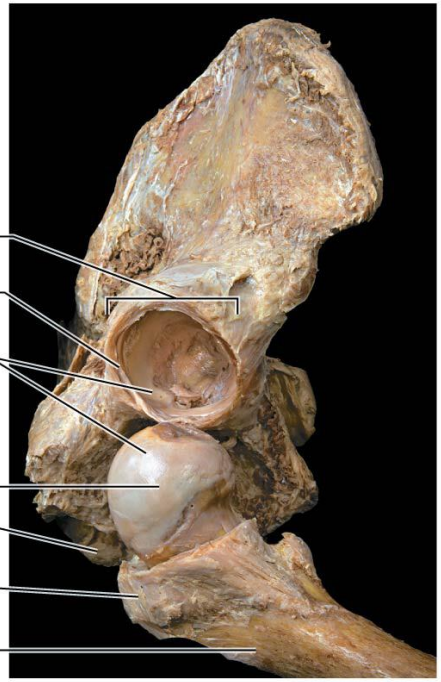

(d) Cadaver photo, lateral view with head of femur removed from acetabulum

Knee Joint

- Largest, most complex joint of body

- Consists of three joints surrounded by a single cavity
  1. **Femoropatellar joint**
     - Plane joint → gliding motion during knee flexion

  2. **Lateral joint** and 3. **Medial joint → tibiofemoral joint**
     - Joint between femoral condyles and **lateral** and **medial menisci** (fibrocartilage discs) of tibia
     - Hinge joint that allows *flexion, extension*, and some *rotation* when knee is partly flexed

Knee Joint

- Joint capsule is thin and absent anteriorly
  - Quadriceps tendon gives rise to three broad ligaments that run from patella to tibia
  - **Medial** and **lateral patellar retinacula** that flank the **patellar ligament**
    - Doctors tap patellar ligament to test knee-jerk reflex

- At least 12 bursae associated with knee joint
- Intracapsular ligaments
  - **Anterior cruciate ligament** (**ACL**)
    - Attaches to anterior tibia
    - Prevents forward sliding of tibia and stops hyperextension of knee
  - **Posterior cruciate ligament**
    - Attaches to posterior tibia
    - Prevents backward sliding of tibia and forward sliding of femur

Knee Joint.

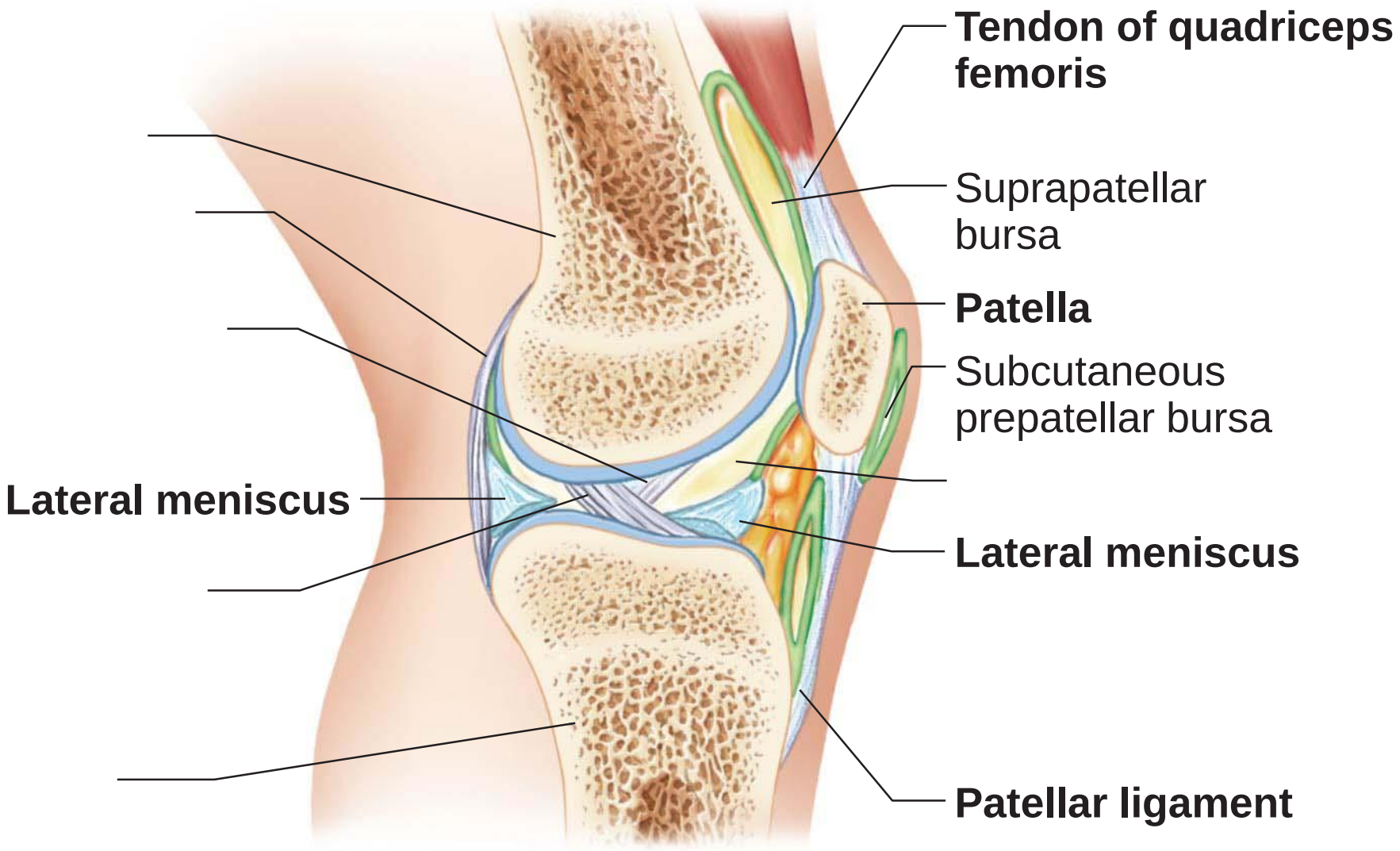

(a) Sagittal section through the right knee joint

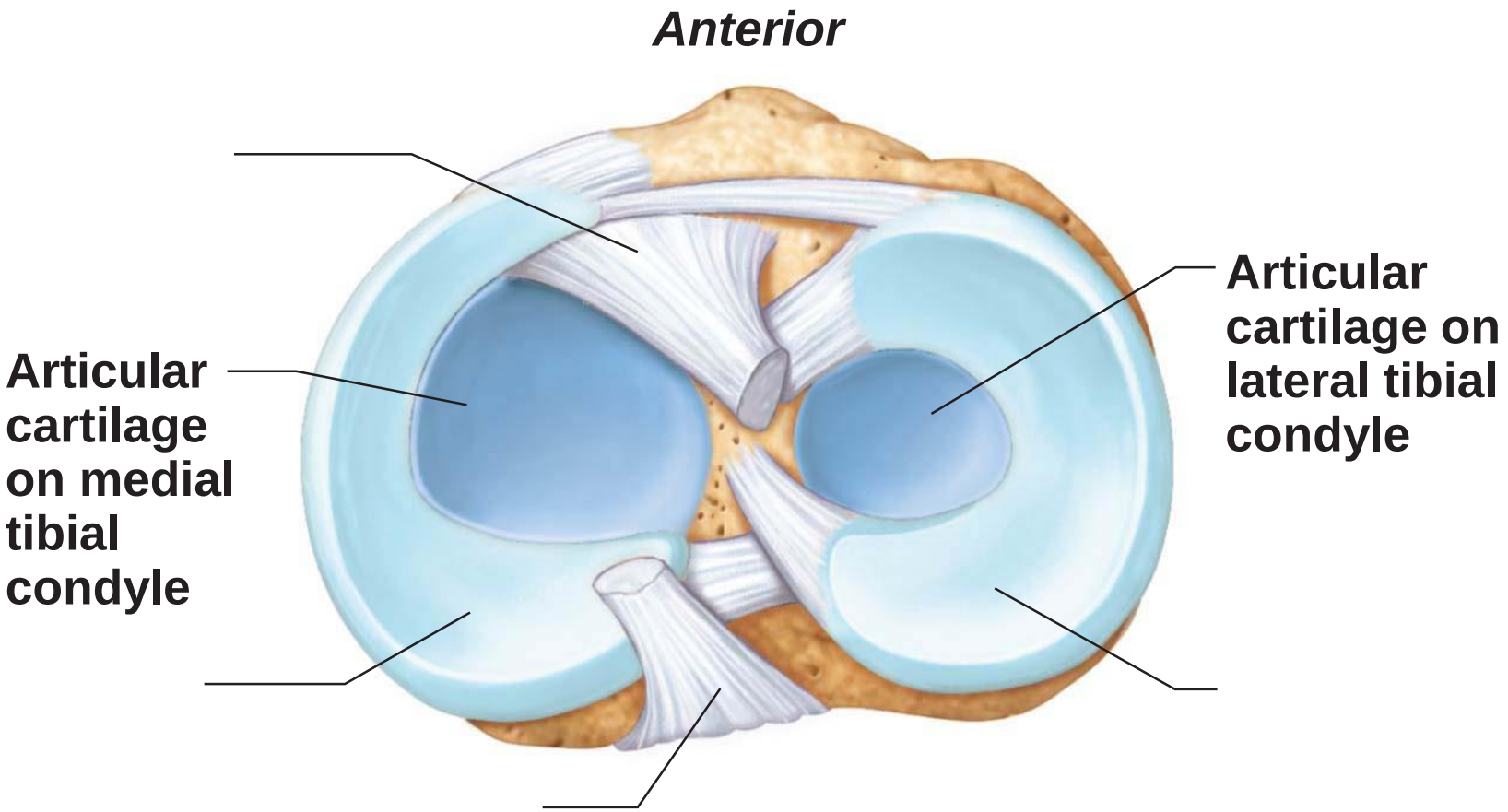

(b) Superior view of the right tibia in the knee joint, showing the menisci and cruciate ligaments

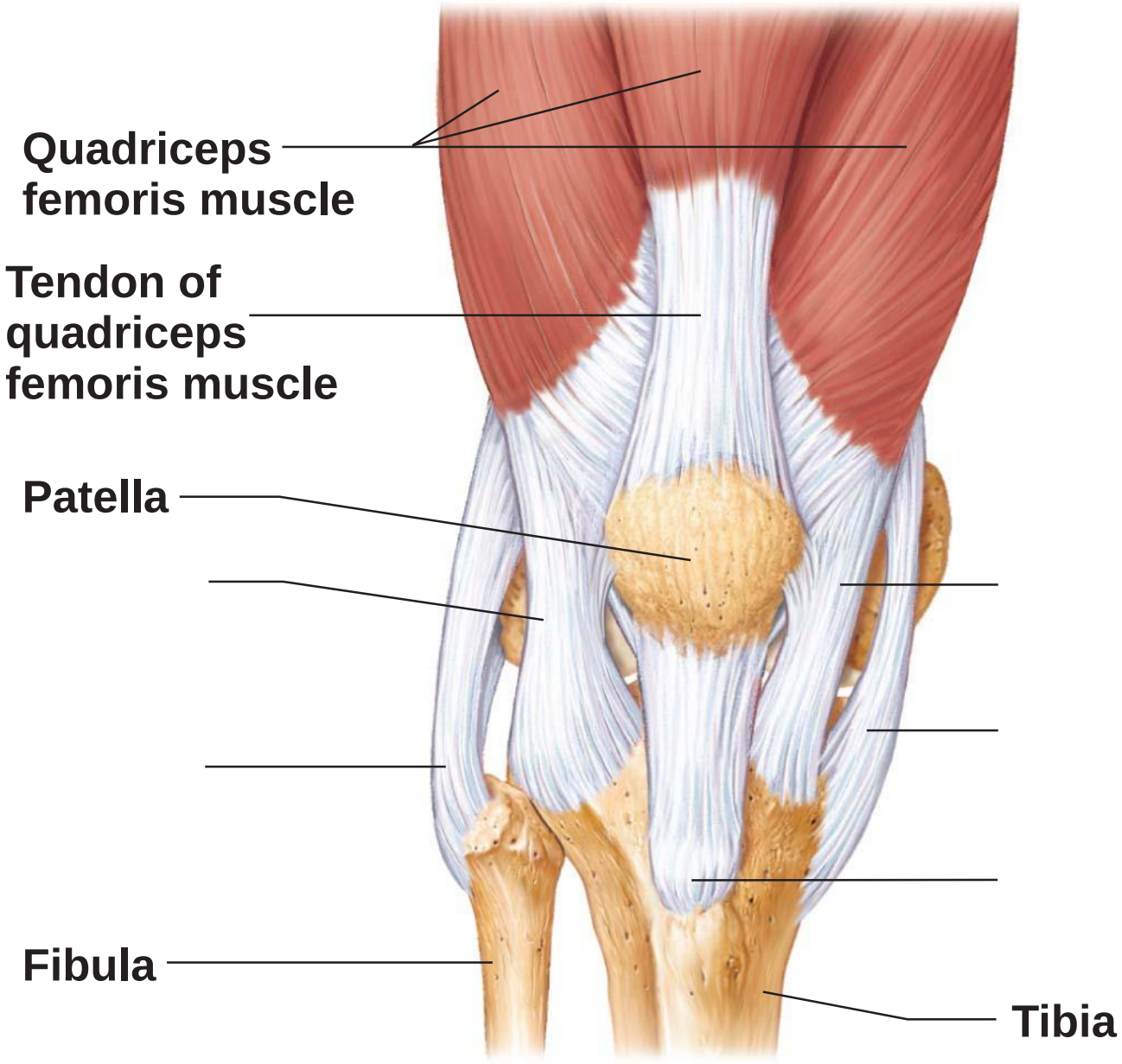

(c) Anterior view of right knee

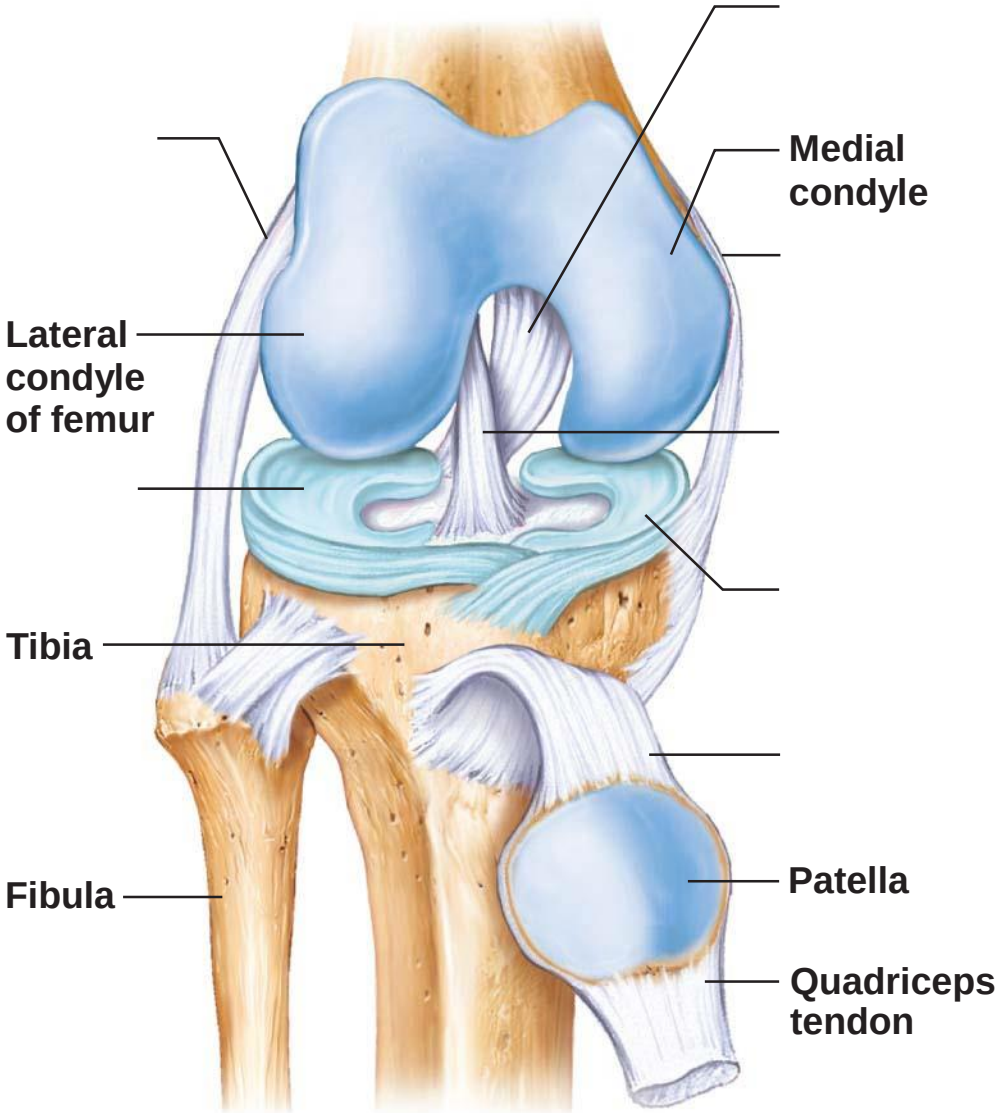

(e) Anterior view of flexed knee, showing the cruciate ligaments (articular capsule removed, and quadriceps tendon cut and reflected distally)

Knee Joint

- Capsular, extracapsular, or intracapsular ligaments act to stabilize knee joint

- Capsular and extracapsular ligaments help prevent hyperextension of knee
  - **Fibular and tibial collateral ligaments**: prevent rotation when knee is extended
  - **Oblique popliteal ligament**: stabilizes posterior knee joint
  - **Arcuate popliteal ligament**: reinforces joint capsule posteriorly

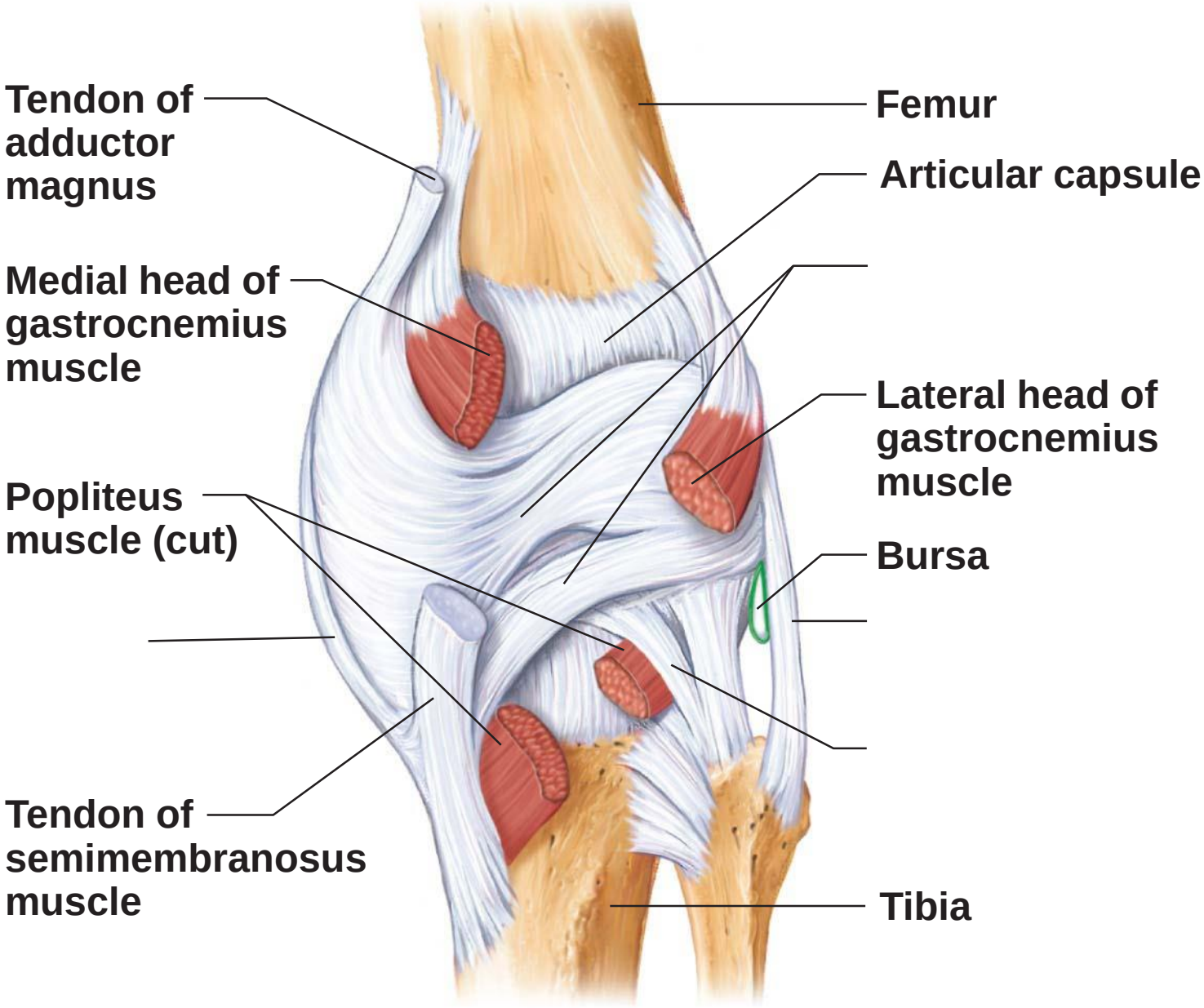

(d) Posterior view of the joint capsule, including ligaments

Common knee injuries involved the 3 C's:

- *Collateral ligaments*
- *Cruciate ligaments*
- *Cartilages (menisci)*

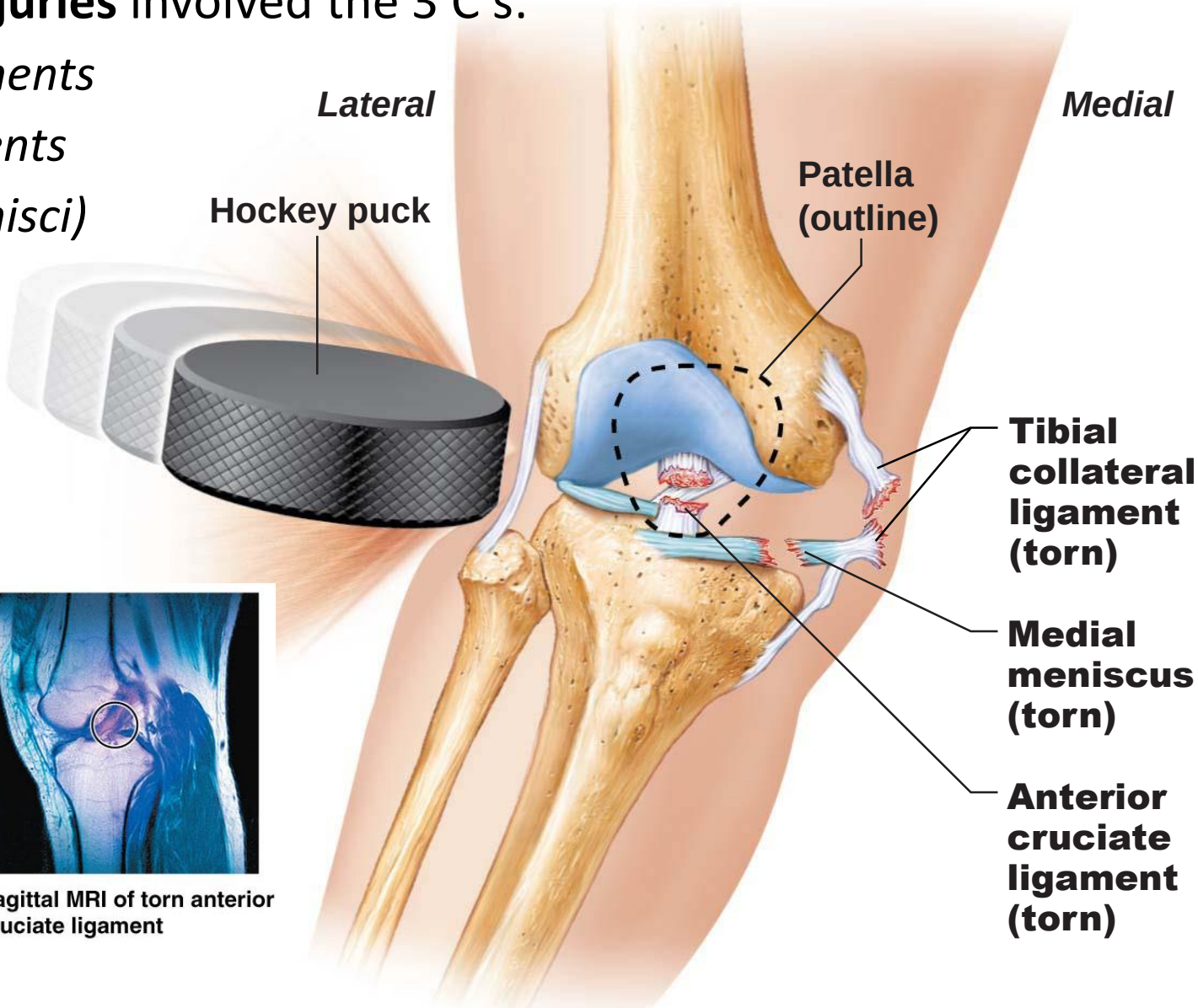

Anterior MRI of torn tibial collateral ligament

Sagittal MRI of torn anterior cruciate ligament

The "unhappy triad:" ruptured ACL, ruptured tibial collateral ligament, and torn medial meniscus.